Original Article

Comparative study of mast cells in different pathological types of surgically resected appendix specimens

Abhijit Banerjee[1], Debasis Bhattacharya[2*], Soma Datta[2], Nikhilesh Dewasi[2], Jyotirmoy Bhattacharyya[3]

{[1]PG Student, [2]Assistant Professor, Department of Pathology} {[3]Associate Professor, Department of Surgery}
Burdwan Medical College, Burdwan-713101, INDIA.
Email: nilanjanbhattacharya2003@gmail.com

Abstract

Mast cells, constantly present in appendix can vary in numbers in normal and pathological states. The objectives are looking for role of mast cells in pathogenesis of appendicitis, their quantitative in normal appendix and appendicitis as well as in different layers of wall of appendix in varied pathological entities and their relationship with eosinophils. One hundred patients were selected and mast cells, eosinophils counted and compared in formalin fixed appendicectomy specimens by H and E, toluidin blue and Van Gieson stains. Females dominated in the study with maximum cases (56%) in the age group of second and third decades. Recurrent appendicitis dominated in the pathological (69%), whereas high eosinophilic count was observed in acute eosinophilic appendicitis and high mast cell count in acute eosinophilic and recurrent appendicitis. A positive correlation with mean eosinophilic and mast cell counts in appendicitis was noted with increasing mast cell count with fibrosis.

Key Words: Mast cell, eosinophil, appendicitis, fibrosis.

***Address for Correspondence:**
Dr. Debasis Bhattacharya, BH-158, Salt Lake, Kalkata-70009, West Bengal, INDIA.
Email: nilanjanbhattacharya2003@gmail.com
Received Date: 10/03/2017 Revised Date: 16/04/2017 Accepted Date: 06/05/2017

Access this article online	
Quick Response Code:	Website: www.medpulse.in
	DOI: 17 May 2017

INTRODUCTION

The biomedical literature included mast cells and basophils in the group of basophilic leucocytes. Paul Ehrlich recognized mast cells for their remarkable staining characteristics of proteoglycan and protease rich cytoplasmic granules1. Mast cells arise from hematopoietic progenitor cells and mature ones usually do not circulate in the blood but acquire their mature phenotype locally in the tissues where they ultimately reside[1]. Mast cells resemble basophils and both are bone marrow derived cells, contain electron dense granules staining metachromatically with selected basic dyes and produce numerous inflammatory mediators like histamine. Both express high affinity receptor for IgE which on activation by anti Ige antibodies induce mediator synthesis and secretions playing important roles in allergic inflammation and immune response. Mast cells mature outside bone marrow, generally in connective tissue or serous cavities, while basophils circulate in blood and recruited during allergic responses[1-3]. Most mast cells primarily found in skin, gastrointestinal tract and respiratory tract are constantly. Present in appendix, the organ most commonly subjected for surgical intervention and removal. Although, clinical and operative protocols are well known but pathogenesis of acute appendicitis is poorly understood. Currently, luminal obstruction due to faecoliths or less commonly submucosal lymphoid hyperplasia especially in children appears to initiate acute inflammation in appendix[1-3]. The present study aims at finding role of mast cells in pathogenesis of appendicitis; their variation in counts in mucosa, submucosa, and muscle layers in different

How to site this article: Abhijit Banerjee, Debasis Bhattacharya, Soma Datta, Nikhilesh Dewasi, Jyotirmoy Bhattacharyya. Comparative study of mast cells in different pathological types of surgically resected appendix specimens. *MedPulse – International Medical Journal.* May 2017; 4(5): 618-624. http://www.medpulse.in (accessed 20 May 2017).

histopathological groups of inflamed appendix compared to uninflamed one in various age groups. The study also looks for relationship between mast cells and fibrosis in appendix as well as relationship between number of eosinophils and mast cells in inflamed appendix.

MATERIAL AND METHODS

The prospective study was conducted in a tertiary care hospital in West Bengal in a time period of one year after taking clearance from the Institutional Ethical Committee and consent from patients. One hundred patients who attended and got admitted in surgery department with appendicitis were included in the cross- sectional observational study where appendices got removed for acute appendicitis, in course of laparotomy and those present with pathological ileocaecal specimens. Exclusion criteria were applicable for cases of acute gangrenous appendicitis with associated necrosis. Appendices fixed in 10% formalin were received by the department of pathology for study. One section from tip, base and body was taken after 24 hours of fixation. Post processing and embedding of tissue sections into paraffin blocks were dine; two sections of five micron thickness cut from each block. One of the sections stained by haematoxylene and eosin (H and E) and the other by one per cent toluidine blue for identification of mast cells. H and E stained sections studied for histopathological evaluation of acute appendicitis with emphasis on presence of eosinophils and fibrosis. Van gieson stain was used to confirm the presence of fibrocollagenous tissue. Toluidine blue stain (1%) was used for identification of mast cells. The number of mast cells in the mucosa, submucosa and muscular layer counted at high power and average counts obtained in ten non-overlapping high power fields considered in each case. Average eosinophil count in all layers in HandE stained sections obtained as described for mast cells. Field of view of eyepiece of microscope used was 18mm and area of field covered by high power objective of microscope was calculated to be 0.4mm2. Considering this data, cell ounts expressed as number of cells per mm2. Further, the relationship of mast cells with eosinophilic infiltrate and fibrosis was also assessed. The relationship between mast cell numbers and degree of eosinophilic infiltration was evaluated using Spearman' rank correlation test. The eosinophil and mast cell counts in various histopathological categories were compared using ANOVA. In H and E staining procedure; sections brought to water, stained with Harris haematoxylene for two to three minutes followed by washing in running tap water. Sections were then differentiated in 1% acid alcohol, washed in running tap water followed by counterstaining with aqueous eosin for two minutes. Dehydration with two to three changes of absolute alcohol was done and cleared with two to three changes of xylene. Finally, sections were mounted by dibutyl phthalate polystyrene xylene (DPX). Nuclei were stained blue and cytoplasm pink in colour. In toluidene blue metachromasia staining procedure, sections deparaffinised through two changes of xylene, absolute alcohol and ninety five per cent alcohol to distilled water. They were then stained in one per cent toluidene blue solution for one to two minutes and rinsed in distilled water. Sections covered, edges of cover slip blotted and sealed with finger nail polish. Microscopical examination was done promptly following preparation which showed purple coloured mast cell granules in blue background. In Van Gieson staining procedure, deparaffinised sections hydrated to distilled water. Nuclei were stained with working solution of Working Weigert's iron haematoxylene for fifteen to thirty minutes and washed in water until nuclei were dark blue-black in paler blue-black background. Staining with Van Gieson's stain was done for three minutes, dehydrated rapidly in alcohol then cleared and mounted. Collagen fibres took red colour; nuclei were brown black and yellow colour visualised in muscle and red blood cells.

RESULTS

The present study conducted on hundred surgically resected specimens of appendix. Of 100 cases; 44 were males (44%) and 56 females (56%) with male to female ratio of 1: 1.7. Age of patients ranged from 7-64 years with mean age of 25.7 years. 1:1.27. Age of patients ranged from 7-64 years with mean age of 25.7 years. Thirty-eight cases (males-16 and females - 22) were in the third decade and 31 cases (males- 14 and females -17) in second decade. Seven appendices (7%) were removed during other surgical procedures without any clinical symptoms of appendicitis and showed normal in gross appearance and histology. Acute appendicitis was diagnosed when patient presented with acute onset of fever, severe umbilical or right lower abdominal quadrant pain with tenderness and vomiting and muscularis propria, submucosa showed infiltration by neutrophils which were accounted in 13 cases (13%). Acute suppurative appendicitis with clinical presentation of acute symptoms and showing dense infiltration of the muscle wall with neutrophils, eosinophils, plasma cells and lymphocytes throughout all layers were seen in 5 cases (5%). Acute eosinophilic appendicitis presenting clinically like classic acute appendicitis with inflamed and oedematous appendix, showing marked eosinophilic infiltration into the mucosal crypts, submucosa, muscular and serosal layers without neutrophils were found in six cases(6%). Maximum number of cases (69%) were of recurrent appendicitis presenting with history of repeated attacks of right lower abdominal quadrant pain greater

than two weeks and pathologic findings of chronic inflammation with or without fibrosis. Forty-four out of 69 cases of recurrent appendicitis were seen above 20 years of age. Among the nine cases of acute appendicitis studied, peak incidence of occurrence was seen in age group above 20. Out of 56 females patients, 40 (71.4%) presented with recurrent appendicitis compared to all other groups. This was statistically significant (p<0.01). Out of 44 males; 29(65.9%) were presented with recurrent appendicitis which was higher compared to other groups, followed by 8 cases (18.2%) of acute appendicitis. Out of 69 cases of recurrent appendicitis higher incidence was seen in females (n=40) (58.0%), which was also statistically significant (p<0.01). The length of appendices studied ranged from 3-8.5 cm with a mean length of 5.56cm. All appendices received were of entire length and 75 appendices (75%) had attached mesoappendix. External surface showed hyperaemia with congested blood vessels in 70 cases. Sixteen appendices were swollen and 5 showed pus on surface. Wall of appendices were thickened in 58 cases and thinned in 11 cases. Mucosal ulceration was seen in 16cases and hyperaemia in 24 cases. Lumen of appendix showed faecolith in 38 of all cases, luminal dilatation was seen in 20 casesand narrowing in 34 cases. Five cases showed pus in the lumen. Lumen showed neutrophilic predominant exudates in 18 appendices and eosinophilic predominant exudates in 6. No parasite was found in the studied cases. Appendiceal mucosa was ulcerated in 41 cases and congested in 52 cases. Neutrophilic predominance was seen in 18 cases and eosinophilic predominance in 6 cases. Maximum number of cases (n=76) showed lymphocytic predominance. Submucosal oedema was seen in 11 cases ; inflammation in 82 with majority (n=76) showing lymphocytic predominance in submucosa followed by neutrophilic predominance in 18 cases and 6 showed predominant eosinophilic infiltration. Seventy-nine cases showed submucosal fibrosis. Fifteen cases showed oedema in the muscularis, 34 cases showed inflammation and fibrosis. Oedema was seen in 10 cases, inflammation in 20, congestion in 60 and fibrosis in 10 cases. Out if 100 appendices studied, maximum number of recurrent appendicitis showed fibrosis in sumucosa (n=62) and muscularispropria (n=24). Patients were divided into two age groups of below and above 20 years and results were analysed. Mean eosinophilic count in mucosa in various histopathological groups in each age group was compared. Highest mean eosinophilic count of 143.75/mm2 was seen in mucosa of acute eosinophilic appendicitis and was statistically significant (p<0.01). It was found that mean eosinophilic count in mucosa was low in acute appendicitis. Mean eosinophilic count in submucosa of appendices in various histolopathological groups in each age group was compared. Highest mean eosinophil count of 43.33/mm was seen in acute eosinophilic appendicitis followed by 32.5/mm2 in acute suppurative appendicitis. It was found that eosinophil count in mucosa were high in acute eosinophilic appendicitis; low in acute appendicitis and normal appendicitis. Mean eosinophil count in the muscularis propria of appendices in various histopathological groups in each age group was compared. Highest number of mean eosinophil count of 65/mm2 was seen in acute eosinophilic appendicitis and that in acute suppurative appendicitis was 25/mm2. Mucosal mast cell count in various histopathological groups in each group was compared. Highest mean mast cell count was

Table 1: Comparison of Mast Cells count in the Mucosa of Appendix.

Histopathological groups	Mean mast cell/mm2		Total mean mast cell count/mm2
	Age 0- 20 years	Age > 20 years	
Normal (n= 7)	6.2	4	4.6
Recurrent (n = 69)	12.3	8.4	10.6
Acute (n = 13)	7.8	7	7.5
Acute suppurative (n = 5)	10	5	8
Acute eosinophilic (n = 6)	0	12.5	12.5

Observed in mucosa of acute eosinophilic appendicitis (12.5/mm2) followed by recurrent appendicitis (10.6/mm2) (Table 1). Mast cell count in submucosa in various histopathological groups of appendices In each group were compared. Highest mean cell count of 28.7/mm2 was seen in acute eosinophilic appendicitis followed by 27.5/mm2 in recurrent appendicitis (Table 2). Mast cell count in muscularis propria of the appendices in the various histopathological groups were compared. Highest mast cell count of 20.4/mm2 seen in acute eosinophilic appendicitis followed by 15.7/mm2 in recurrent appendicitis (Table 3). Appendicectomy specimens from both genders did not show any significant differences in mast cell count in any of the layers. Highest mean mast cell count was seen in

Table 2: Comparison of Mast Cell Counts in the submucosa of Appendix

Histopathological groups	Mean mast cell/mm2		Total mean mast cell count/mm2
	Age 0- 20 years	Age > 20 years	
Normal (n=7)	11.2	7.5	8.6
Recurrent (n=69)	25.9	28.3	27.5
Acute (n=13)	18.2	26.7	22.1
Acute suppurative (n = 5)	24.2	16.2	19.0
Acute eosinophilic (n = 6)	0	28.7	28.7

Table 3: Comparison of Mast Cell Counts in the Muscularis Propria of Appendix

Histopathological groups	Mean mast cell/mm2		Total mean mast cell count/mm2
	Age 0-20 years	Age > 20 years	
Normal (n=7)	6.25	4	4.64
Recurrent (n=69)	16.9	15.7	15.8
Acute (n=13)	9.3	15.8	12.3
Acute suppurative (n=5)	15.8	5	11.5
Acute eosinophilic (n=6)	0	20.4	20.4

Acute eosinophilic appendicitis and lowest found in normal appendices. Recurrent appendicitis showed higher mean mast cell count (Fig 1, toluidene blue, x 100) compared to other inflammed appendices. Acute appendicitis and acute suppurative appendicitis showed intermediate counts. A positive correlation established using Pearson's test between mean eosinophilic counts/mm2 and mean mast cell count/mm2 in the different layers of appendix in various histopathological groups showing trend towards significance($p<0.05$). Mast cell count in mucosa was found to be higher in acute eosinophilic appendicitis and recurrent appendicitis with or without fibrosis as compared to other inflamed appendices. Submucosal mean mast cell count was higher in acute eosiniphilic appendicitis and recurrent appendicitis when compared to other inflamed appendices and showed a trend towards significance ($p<0.05$). No significant difference was observed in mean mast cell count in the different layers of appendices in each age group.

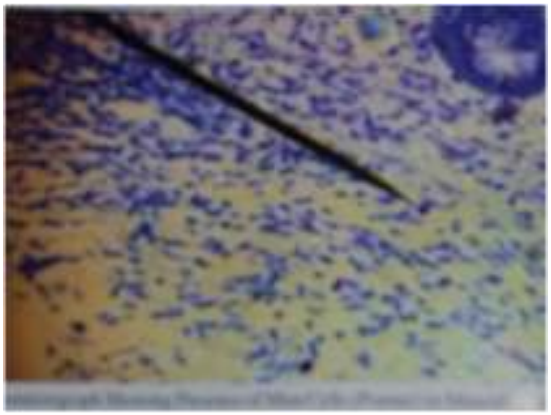

Figure 1: Pholomicrograph Showing Presence of Mast Cells (Pointer) in Muscular Layer in Recuurent Appendicitis

DISCUSSION

The surgically resected appendices of 100 patients were grossly and histopathologically evaluated along with mast cell and eosinophil counts. Appendix since long was erroneously viewed as vestigial orgn with no known function. It is now recognized that appendix is an immunological organ that actively participates in secretion of immnunoglobulins, particularly immunoglobulin A3-7. In the present study, out of 100 resected appendices, 44 were males and 56 females with male to female ratio of 1: 1.27.Highest incidence of appendicectomy was seen in third decades with mean age of 25.7years. Chang8 in his analysis of 3003 appendices found a slight preponderance of males. He found that 82% of appendices removed from the patients were less than thirty years of age, similar to the present study. Male predominance of acute appendicitis was also seen by Elangovan *et al*[4]and Singh *et al*[9] which was consistent with present study. Petras and Goldblum10 showed common occurrence of appendicitis in second and third decades with incidence falling gradually after 40 years of age, equally affecting males and females with affection of females more in 15-25 years group with female to male ratio of 2:1. This difference is not noted in other age groups. Rosai5 observed acute appendicitis seen in either sex at any age but most frequently in young men. He also noted that a false positive diagnosis was twice as common in females and males. Appendix in cases of repeated episodes shows fibroisis indicative of previous inflammation. However, existence of recurrent appendicitis has always been controversial and only readdressed6. In the present study, recurrent appendicitis was seen more frequently than acute appendicitis. The incidence of recurrent appendicitis was higher above 20 years of age. A significantly high incidence of recurrent appendicitis was seen in females in this study. Chang and chan11 noticed an 11% incidence of recurrent appendicitis out of 290 patients with appendicitis comprising 21% females. The diagnosis was retrospective, as the patient had to be symptom –free after surgical removal of appendix; 15% of patients had more than three previous episodes of right iliac fossa pain, attributed to recurrent inflammation of appendix. Thackray12 found that histological features of progressive fibrosis with infiltration by lymphocytes and plasma cells together with hyperplasia of lymphoid tissue are normally present. Crabbe *et al13*fount 10% incidence of recurrent appendicitis and cautioned that to deny the existence of these clinical presentations may needlessly delay surgical treatment in patients with recurrent appendicitis. Barber *et al14* concluded that recurrent appendicitis exists and affects at least 6.5% of those who ultimately have an inflamed appendix removed. In the present study, no case of chronic appendicitis was found which collaborated with most of the authors. They were probably represented as recurrent appendicitis as noted by Hertzler15. In the present study of 100 case, no case of subacute appendicitis was found but showed 5% of acute

suppurative appendicitis. Stephenson and Snoddy7 classified appendices having polymorphonuclear leucocyte infiltration of musclewall, with or without other inflammatory cell infiltration as acute suppurative appendicitis. Most of these appendices showed dense infiltration of neutrophils in the muscular layer and constituted 28.6% of inflammatory lesions of appendix in their study. Eosinophils as a role infiltrate in the muscle layer in appendicitis have been described previously. Strphenson and Snoddy7chose to cell it "subacute appendicitis" when there is an infiltration of muscle wall by at least five eosinophils/high power field but failed to mention the clinical correlation to justify this term. Jona *et al*[16] observed cases which presented as acute appendicitis but containing only transmural eosinophilic infiltration in appendix and included them in the spectrum of eosinophilic gastro-enteritis rather than primary appendicitis. Aravindan17 observed mural eosinophilic infiltration as consistent finding in acute appendicitis and described cases where eosinophilic infiltrate was the sole finding. He was the first to suggest that eosinophilic infiltration in acute appendicitis is an early event linked possibly to type I hypersensitivity reaction. In another study, Aravindan *et al*[18] described cases which presented clinically like classic acute appendicitis, where an inflamed and oedematous appendix does not show neutrophils in the muscle layer, but marked eosinophil infiltration instead. He chose to name this entity as "acute eosinophilic appendicitis ". In the present study, 6 out of 100 appendices showed the histological features fitting into the category of acute eosinophilic appendicitis, the incidence of which was similar to that seen by Aravindan[17]. A significantly high mean eosinophil count in all the three layers is seen in acute eosinophilic appendicitis when compared to normal and in other histopathological groups of appendicitis as in the present study also. In this study, higher mucosal mast cell count was seen in acute eosinophilic appendicitis and recurrent appendicitis. Intermediate count were seen in mucosa of acute appendicitis and accute suppurative appendicitis. Crowe and Howe19 showed high mucosal mast cell count in normal appendix. This was in contrast to present study which showed very low mast cell count in normal appendix. Naik *et al*[20] found that mean mast cell count were decreased in mucosa and submucosal layers of acute appendicitis. They concluded that the cause of decreased mast cell count is due to inability to detect them because of degranulation or elimination through mucosa. Aravindan17 and Aravindan *et al*[18] found wide range of mean mast cell count in normal appendices. They suggested that normal appendices with high initial mural mast cell count are prone to develop acute appendicitis. Mysorekar *et al*[21] studied 150 appendices, out of which 6 showed normal histology and these appendices showed very low mast cell count in all the laters similar to that seen in the present study. They found a higher mast cell count in acute appendicitis compared to normal appendices but chronic appendicitis showed highest mast cell count. Singh *et al*[9] found highest mean mast cell count in clinically acute but histological normal appendicitis. They remarked that a statistically significant increase in mast cells in appendices which appear normal on histology but clinically have symptoms of acute appendicitis may explain the clinical presentation and opined that pain in these patients may be caused by degranulated mast cells. In the present study, submucosal mean mast cell count was lowest in normal appendix which was in concordance with Mysorekar *et al*[21] and Singh *et al*[9]. *Naik et al*[20] found high mean mast cell count in normal appendices and subacute appendicitis. In the present study, highest mean mast cell count was seen in acute eosinophilic appendicitis and recurrent appendicitis and vary low in normal appendices similar to studies by Mysorekar *et al*[21] and Singh *et al*[9]. In the present study, a higher mast cell count was observed in the muscularis propria in recurrent appendicitis when compared to acute appendicitis. Lowest mean mast cell count was seen in normal appendices which is in concordance with other authors. Highest mean mast cell count was observed in cases of acute eosinophilic appendicitis. Aravindan7 found high mean mast cell count in muscular layer of recurrent appendicitis which was also found in the present study. Mysorekar *et al*[21] found highest mean mast cell count in the muscular layer, lymphocytes and plasma cells with presence of submucosal lymphoid hyperplasia and varying degree of fibrosis. In the present study, the term chronic appendicitis was avoided since its existence has been disputed. Instead, the term recurrent appendicitis used for the cases showing similar histological features aling with a clinical history of repeated bouts of abdominal pain in the past. Crowe and Howe19 and *Naik et al*[20] found a higher mucosal mean mast cell count in children as compared to older patients. The present study did not show any such difference which was similar to study by Mysorekar *et al*[21]. There was no correlation between sex and mast cell count in the present study as has also been described by Naik *et al*[20] and Myosorekar *et al*[21]. Aravindan17 found that mast cells tent to be few and degranulated in areas which showed clustering of eosinophils. Naik *et al*[20] suggested that eosinophils are attracted to eosinophilic chemotactic factor or histamine release from the mast cell granules. Singh *et al*[9] also observed an increase in mean mast cell count in different layers with corresponding increase in mean eosinophilic count and attributed it to the chemotactic factor and histamine release from mast cells. In contrast, Mysorekar

et al[21] did not find any correlation between mast cell and eosinophil density or distribution. In the present study, a positive correlation was found between mast cell and eosinophil count was seen in acute eosinophilic appendicitis which also showed highest mean eosinophil count in all the layers. Stead *et al*[22] found appendices with fibrosis have higher mast cell count and histamine. They postulated that nerve growth factor causes hyperplasia of both mucosal and submucosal mast cells and that certain fibroblasts have the ability to make nerve growth factor. Naik *et al*[20] observed a rise in mast cell count in early stages of fibrosis and as the fibrosis increased this association was retained only in submucosa. The present study showed fibrosis in 62% cases in submucosal and muscularis layers. These showed a concurrent higher mast cell count as compared to other inflammatory appendices. The mast cell mediators are involved in different acute and chronic inflammatory and repair processes. Increased mast cells are demonstrated in repair processes 23-26. In the present study. Out of 100 appendices studied 41% showed faecoliths and only 3 cases (23%) of acute appendicitis and 38 cases (55%) of recurrent appendicitis showed faecolith. Burkitt[25] suggested that the main cause of appendicitis was removal of much of cellulose content of our food. Many authors[25,26] have proved that appendicitis may develop from causes unrelated to obstruction of appendiceal lumen. It is also well recognized that faecoliths may be present in the appendiceal lumen without causing obstruction or without accompanying evidence of inflammation. Aravindan17 opined that though obstruction can set into motion the chain of events which lead to mucosal damage and infections, obstruction as a primary cause is overrated. Mysorekar *et al21* found faecolith in only 20.1% cases. Elangovan *et al*[28] found no association between presence of faecolith and acute appendicitis. In the present study,none showed evidence of parasitic infestation. Dorfman *et al*[29] and Addiss and juranek30 found no significant causal relationship between parasitic infestation and acute appendicitis. Mysorekar *et al*[21] found a more 2.1% of cases showing evidence of parasitic infestation. Dahlen and Kumlin 31 stated that although many mast cell mediators or products serve as useful markers of mast cell activation in vitro, it has been notoriously difficult conclusively to establish mast cell activation in human studies. Tsuji *et al32* suggested that antigen stimulation of effector system could give rise to appendicitis. Aravindan17 postulated that the preinfective atage is a type 1 hypersensitivity reaction involving IgE mediated responses as part defence mechanisms of bowel and may produce enough swelling to compromise the blood supply and thereby damage the mucosa when submucosa and muscle are massively involved and cause acute inflammation.Mysorekar *et al*[21] also favours this theory in preference to obstruction for causation of appendicitis. Thus, findings in the present study favour the theory of hypersensitivity which plays an important role in causation of appendicitis.

CONCLUSIONS

A higher incidence of recurrent appendicitis was found in this study. Eosinophil counts in all the layers were very low in normal appendices and very high in acute eosinophilic appendicitis and acute appendicitis. A higher mast cell count was seen in acute eosinophilic appendicitis and recurrent appendicitis. Obstruction by faecolith demonstrated in few cases of appendicitis and there were no cases of parasitic infestation.

REFERENCES

1. Befus AD, Denburg JA. Basophilic leukocytes: mast cells and basophils. In : Wintrobe's Clinical Hematology. 11 th ed. Voll. Philadelphia: Lippincot Williams and Wilkins,2004 : 636-60.
2. Peters SP, Schleimer RP, Naclerio RM. The pathophysiology of humen mast cells,in vitro and vivo function. Am Rev Respir Dis 1987; 135:1196-200.
3. Galli SJ, Tsai M. Mast cells: versatile regulators of inflammation, tissue remodeling,host defense and homeostasis. J Dermatol Sci 2008; 49:7-19.
4. Elangovan S, Knapp DP, Kallail KJ. Incidence of caute appendicitis confirmed by histopathologic diagnosis. Kans Med 1997; 98:10-3.
5. Rosai J. Gastrointestinal tract. In : Rosai J, editor. Rosai and Ackerman's Surgical Pathology. 9th ed. New Delhi: Elsevier, 2004 : 615-872.
6. O' Connell PR. The vermiform appendix. In : Williams NS, Bulstrode CJ, editors. Bailey and Love's Short Practice of Surgery. 25 th ed. London: Holder Education, 2008:1204-18.
7. Stephenson j, Snoddy WT. Appendiceal lesion : observation in 4000 appendecectomies. Arch Surg 1961; 83:661-6.
8. Chang AR. An analysis of the pathology of 3003 appendices. Aust N Z J Surg 1981; 51: 169-78.
9. Singh UR, Malhotra A, Bhatia A. Eosinophils, mast cells, nerves and ganglion cells in appendicitis. Indian J Surg 2008; 70:231-4.
10. Petras RE, Goldblum JR. Appendix. In : Damjanov I, Linder J, editors. Anderson's Pathology. Voll. 10 th ed. St Louis: Mosby Year Book, 1996:1728-40.
11. Chang SK, Chan P. Recurrent appendicitis as a cause of recurrent right iliac fossa pain. Singapore Med J 2004; 45:6-8.
12. Thackray AC. Chronic appendicitis: some pathological observations. Br J Radiol 1959; 32:180-2.
13. Crabbe MM, NorwoodSH. Robertson HD, silva JS. Recurrent and chronic appendicitis. Surg GynecolObstet 1986; 163:11-3.
14. Barber MD, McLaren J, Rainey JB. Recurrent appendicitis. Br J Surg 1997; 84:110-2.

15. Hertzler AE. An enquiry into the nature of chronic appendicitis. Am J Obstet Gynecol 1926; 11:155-70.
16. Jona JZ, Belin RP, Burke JA. Eosinophilic infiltration of the gastrointestinal tract in children. Am J DisChild 1976; 130:1136-9.
17. Aravindan KP. Eosinophils in acute appendicitis: possible significance. Indian J Pathol Microbiol 1997; 40:491-8.
18. Aravindan KP, Vijayaraghavan D, Manipadam MT. Acute eosinophilic appendicitis and the significance of eosinophil oedema lesion. Indian J Pathol Microbiol; 53:258-61.
19. Crowe J, Howe S. Mast cell numbers in appendices with threadworm infestation. J Pathol 1988; 154:347-51.
20. Naik R,Pai MR, Bansal R, Pai R. Relation of mast cell, nerve and fibrosis in appendix. Indian J PatholMicrobiol 1998; 41:27-30.
21. Mysorekar VV, Chanda S, Dandeka CP. Mast cells in surgically resected appendices. Indian PatholMicrobiol 2006; 49:229-33.
22. Stead RH, Franks AJ, Goldsmith CH, Bienenstock J, Dixon MF. Mast cells, nerves and fibrosis in the appendix: a morphological assessment. J Pathol 1991; 161:209-19.
23. Crivellato E, Beltrami C, Mallardi F, Ribatti D. Paul Ehrlich's doctoral thesis: a milestone in study of mast cells. Br J Haematol 2003; 123:19-21.
24. He SH. Key role of mast cells and their major secretory products in inflammatory bowel disease. World J Gastroenterol 2004; 10:309-18.
25. Kumar V, Abbas AK, Fausto N, Aster JC. Diseases of immune system. In Kumar V, Abbas AK, Fausto N, Aster JC, Editors. Robbins and Cotran Pathologic Basis of Disease. 8 th ed. New Delhi: Elservier, 2010:183-258.
26. Galli SJ,Dvorak HF. Basophils and mast cells : morphologic insights into their biopsy, secretory patterns and functions. Prog Allergy 1984; 34:1-141.
27. Burkitt DP. The aetiology of appendicitis. Br J Surg 1971; 58:695-9.
28. Elangovan S, Knapp DP, Kallail KJ. Incidence of acute appendicitis confirmed by histopathologic diagnosis. Kans Med 1997; 98:10-3.
29. Dorfman S, Cardazo J, Dorfman D, Del Villar A. The role of parasites in acute appendicitis of Paediatric paients. Invest Clin 2003; 44:337-40.
30. Addiss DG, Juranek DD. Lack of evidence for a casual association between parasitic infections and acute appendicitis. J Infect Dis 1991; 164:1036-7.
31. Dahlen SE, Kumlin M. Monitoring mast cell activation by prostaglandin D2 in vivo. Thorax 2004; 59:453-5.
32. Tsuji M, McMohan G, Reen D, Puri P. New insights into pathogenesis of appendicitis based on immunocytochemical analysis of early immune response. J Pediatr surg 1990; 25:449-52.

Source of Support: None Declared
Conflict of Interest: None Declared