Original Article

Evaluation of thyroid lesions by fine needle aspiration cytology in a tertiary hospital – A one year retrospective study of 241 cases

Vetri Veeran Sakkaravarthi[1], Murali Prasth[2*]

[1]Professor and HOD, [2]Assistant Professor, Department of Pathology, Government Thiruvarur Medical College, Thiruvarur- 610004, Tamil Nadu, INDIA.
Email: vjprakashcr@gmail.com

Abstract

Background: In the past 5 or 6 decades FNAC has been increasingly used for investigation of thyroid cases. Like any other organ, FNAC in thyroid is primarily performed to distinguish benign and malignant lesions. Our study was aimed at evaluation of thyroid lesions with histopatholgical correlation where necessary. **Materials and methods:** Our study was a retrospective study in which 241 cases were analysed over a period of one year with histopathological correlation. The sensitivity, specificity, true positivity, false positivity, true and false negativity along with predictive values and diagnostic accuracy were used for statistical analysis. **Results:** Out of 241 cases, 222 were females and 19 were males.25 cases underwent thyroidectomy and histopathological correlation was obtained. Out of 25 cases,17 were benign and 8 were confirmed to be malignant. There was one false negative case of colloid goiter diagnosed as papillary thyroid carcinoma by Histopathology. The sensitivity and specificity was 75% and 100% respectively. The diagnostic accuracy rate was 94% in our study. **Conclusion:** In Rural medical college hospitals where there is shortage of facilities like immunocy to chemistry, FNAC along with clinical data and Ultrasound examination has undoubtedly proven to be an excellent investigation tool in the evaluation of thyroid lesions.

Key Word: Fine Needle Aspiration Cytology, Bethesda system, Accuracy, Histopathology.

***Address for Correspondence:**
Dr. Murali Prasth, Assistant Professor, Department of Pathology, Government Thiruvarur Medical College, Thiruvarur- 610004, Tamil Nadu.
Email: vjprakashcr@gmail.com
Received Date: 11/03/2017 Revised Date: 22/04/2017 Accepted Date: 14/05/2017

Access this article online	
Quick Response Code:	Website: www.medpulse.in
	DOI: 26 May 2017

INTRODUCTION

FNAC of thyroid has been increasingly utilized for investigation of thyroid lesions.[1].The simplicity, diagnostic accuracy and most of all cost effectiveness has given FNAC the status of first line diagnosic test in preoperative evaluation of thyroid lesions. The five main indications of FNAC in thyroid lesions are[1] 1.Evaluation of solitary thyroid nodules. 2. Diffuse thyroid lesions 3.Confirmation and categorization of clinically obvious thyroid malignancy, 4.To obtain material for ancillary tests/prognostic parameter. 5. Evaluation of small lesions suspicious of malignancy but smaller size Thyroid nodule is a common entity but the prevalence of palpable nodules is only 4 to 7 %.Ultrasound is far more sensitive than palpation and can detect nodules of any size. Along with cytology, the clinician is empowered to decide if surgical excision of a thyroid nodule is warranted.[2] Hence the combination of clinical data, ultrasound and cytology can distinguish effectively benign and malignant swellings of thyroid[3].

MATERIALS AND METHODS

Our study was a retrospective study conducted on 241 patients in a growing tertiary medical centre in a rural area over a period of one year between 2015 to may 2016.The aim was to determine the cytological patterns of thyroid lesion and accuracy of FNAC in the investigation of thyroid lesions. The patients either had a diffuse or nodular enlargement. Information regarding age, sex, clinical data, ultrasound and histopathological

How to site this article: Vetri Veeran Sakkaravarthi. Murali Prasth. Evaluation of thyroid lesions by fine needle aspiration cytology in a tertiary hospital – A one year retrospective study of 241 cases. *MedPulse – International Medical Journal.* May 2017; 4(5): 697-700. http://www.medpulse.in (accessed 28 May 2017).

data were gathered from the registers. The technique of FNAC used was non-aspiration using a 23-25 gauge needle. Wet fixed smears with 95%alcohol for 20 minutes and staining was done with Hematoxylin and eosin followed by light microscopic examination.

RESULTS

Out of 241 patients, 222 were female substantiating the high female to male ratio of thyroid disorders and 19 were males. The age distribution of patients was between 13 to 67 years.25 patients underwent thyroidectomy and histopathology was done. The histopathological reports were used for correlation.

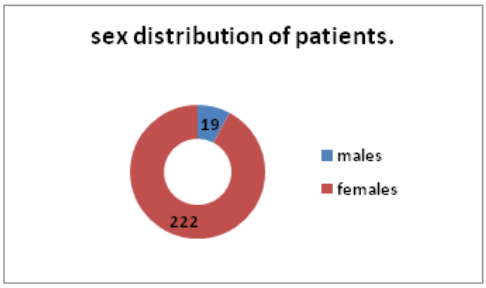

Chart 1: sex distribution

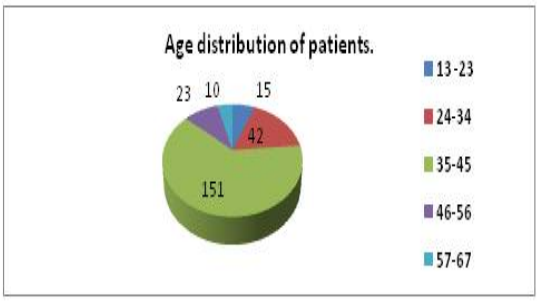

Chart 2: Age distribution

Table 1: FNA cytology results

Lesions (n=241)	frequency	Percentage.
Unsatisfactory	06	2.48
Benign	222	92.11
Suspicious	10	4.15
Malignant	03	1.25

Table 2: Distribution of benign, suspicious and malignant lesions

Benign:(n=222)	Frequency	Percentage.
Colloid goiter.	174	78.3
Hashimoto's thyroiditis	42	18.9
Hyperplastic goiter	05	2.25
Thyroglossal cyst	01	0.95
Suspicious:(n=10)		
Follicular neoplasm	7	70
Hurthle cell neoplasm	3	30
Malignant:(n=3)		
Papillary carcinoma	2	66.6
Medullary carcinoma	1	33.33

Among the 25 patients who underwent thyroidectomy and histopathology performed,17 were confirmed as benign and 8 were diagnosed as malignant.

Table3: Distribution of malignant cases confirmed by HPE

Papillary carcinoma	5	62.5%
Follicular carcinoma	2	25%
Medullary carcinoma	1	12.5%

Figure 1: Low power photomicrograph

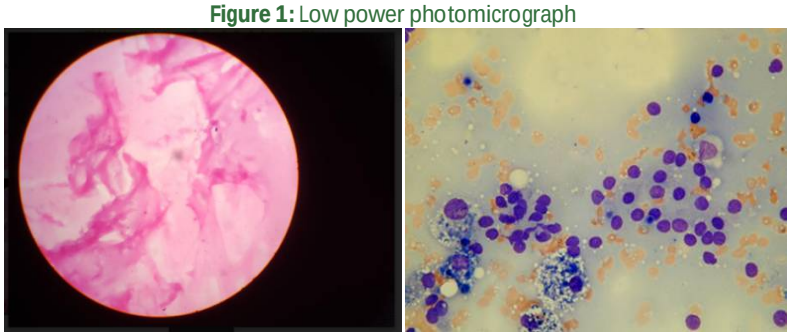

Figure a **Figure b**

Legend

Figure a: showing abundant eosinophilic colloid with follicular cells-colloid goiter. High power view

Figure b: showing benign follicular cells (MGG).

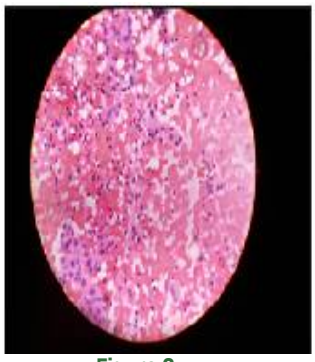
Figure 2

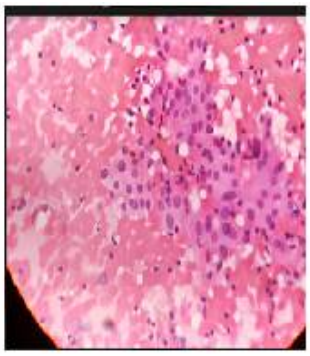
Figure 3


Figure 4(a)

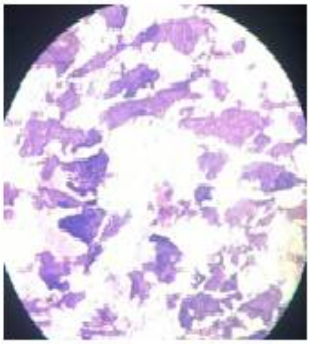
Figure 4(b)

Legend

Figure 2: Low power photomicrograph showing lymphocytes embracing thyroid follicles-Lymphocytic or Hashimoto's Thyroiditis.

Figure 3: High power view showing oxyphilic hurthle cells with abundant eosinophilic granular cytoplasm-Hashimoto's thyroiditis.

Figure 4: Low power view showing finger like papillary clusters of malignant thyroid follicular cells with anatomical edges-papillary carcinoma

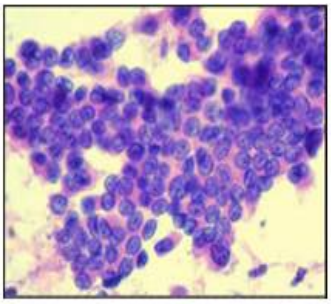
Figure 5(a)

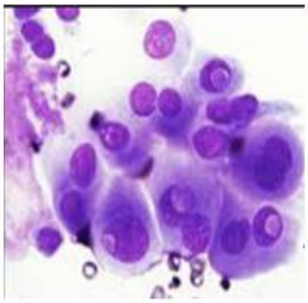
Figure 5(b)

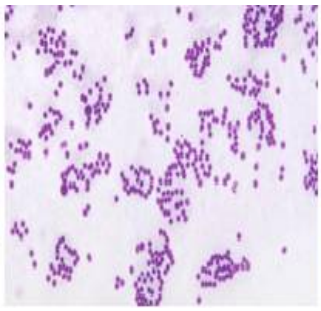
Figure 6(a)

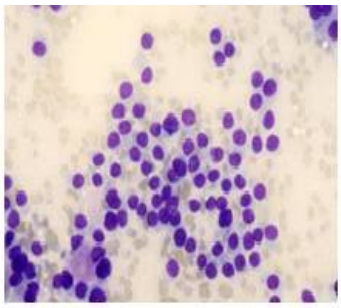
Figure 6(b)

Legend

Figure 5A and 5B: High power view showing nuclear grooves and intranuclear cytoplasmic inclusions-papillary carcinoma of thyroid.

Figure: 6A and 6B: Low power view of follicular neoplasm showing repetitive follicular pattern.

There were no false positives in our study. One false negative diagnosed as colloid goiter showed features of papillary carcinoma.In the suspicious category 3 cases were confirmed as malignant and 1 as benign.

Table 4: Correlation FNAC and HPE (n=25)

FNAC	n=25	Histopathology	
		Benign	Malignant
Inadequate.	1	0	1
Benign	17	16	1
Suspicious	4	1	3
Malignant	3	0	3

Table 5: TP True positive, FP: False positive, TN: True negative, FN: False negative.

Statistical parameter	Formula	Value%
Sensitivity	TP/(TP+FN)*100	75.
Specificity	TN/(TN+FP)*100	100.
Positive predictive value	TP/(TP+FP)*100	100.
Negative predictive value.	TN/(TN+FN)*100	94.1.
Diagnostic accuracy	TN+TP/TP+FN+TN+FP*100	95.

Table 6: Comparison with other studies

Name of the study	No.of patients	Sensitivity	Specificity	Diagnostic accuracy
Kumar *et al*	89	77	100	97
Naggada *et al*	102	88.9	96.1	94.2
Our study.	241	75	100	95

DISCUSSION

Thyroid nodules are common entities that a thyroid surgeon must evaluate. Nodules are found through physical exam, or incidentally through imaging modalities performed for other reasons. The majority of thyroid nodules are benign, but they warrant surgical excision when they are large enough to be symptomatic or if there is concern for malignancy[2] Fine needle aspiration cytology of the thyroid gland has radically changed the management of patients with thyroid disease. FNAC is widely accepted as the most accurate, sensitive, specific, and cost-effective diagnostic procedure in the preoperative assessment of thyroid nodules. The accuracy of the FNAC analysis approaches 95% in the differentiation of the benign nodules from the malignant nodules of the thyroid gland. FNAC of the thyroid swellings is reported to have a sensitivity range of 65-98% and a specificity of 72-100%[3]. The vast majority of clinically diagnosed thyroid nodules are benign, with carcinoma occurring in approximately 5-20% of the cases. (4). The 6‑tiered BSRTC (Bethesda system of reporting thyroid conditions) system is very useful for triaging patient with thyroid nodules for clinical management. In our study, age of patient ranged from 13 years to 67 years with maximum number of patients are the third to fourth decades. Thyroid nodules are more common in females than in males in our study which is similar to other studies. The correlation of cytological and histopathological diagnoses is an important quality assurance method as it allows cytopathologists to calculate their false positive and false negative results[5]. Degirmenci *et al.* reported that the highest specimen adequacy rate was observed among nodules smaller than 1 cm (76.4%) and the lowest rate was ob-served among nodules larger than 3 cm (56.9%). They inferred that the lower rate in larger nodules probably resulted from increased vascularity and the larger size of blood vessels, with resultant blood staining of the material[6]. It is difficult to differentiate follicular/Hurthle cell adenoma from carcinoma on cytological assessment because cytology cannot evaluate the criteria of vascular or capsular invasion or of intrathyroid spread[7] The reported false-negative rate ranges from 1% to 19%. However, it is difficult to know the true frequency of false-negative results because only a small percentage (approximately10%) of patients with benign cytologic findings undergo surgery. It has been postulated that the true false-negative rate is below 5% if all patients with thyroid FNA also have a histologic examination[8]. In our study false negative rate was 4%. Commonest malignancy detected was papillary carcinoma in 12 patients[9]. In our study also commonest malignancy was papillary carcinoma. Although FNA cytology is a very reliable and powerful screening method in the preoperative diagnoses of thyroid nodule, long standing experience is needed. Hence, if the information gathered from history, physical examination, USG and test results (Thyroid function tests, SC, CT, etc) were integrated with FNA cytology, decision for surgery may be more accurate[10].

CONCLUSION

FNAC is safe, reliable and cost effective simple procedure to evaluate the thyroid lesions in a tertiary centre where there is shortage of facilities such as immunocyto chemistry and molecular studies. But the combination of clinical data, ultrasound and FNAC (Triple evaluation) has undoubtedly proven to be very effective in the evolution of thyroid lesions.

REFERENCES

1. Orell R S, Sterret GF, Fine Needle Aspiration cytology, Fifth edition. pages 118-119.
2. Steven R. Bomeli, MD, Shane O. LeBeau, MD, and Robert L Ferris, MD, PhD *Otolaryngol Clin North Am*. 2010 April ; 43(2): 229–238. doi:10.1016/j.otc.2010.01.002.
3. Bagga P K, Mahajan N C. Fine needle aspiration cytology of thyroid swellings: How useful and accurate is it?. Indian J Cancer 2010; 47: 437-42.
4. Bamanikar S, Soraisham P, Jadhav S, Kumar H, Jadhav P, Bamanikar A. Cyto-histology and clinical correlation of thyroid gland lesions: A 3 year study in a tertiary hospital. Clin Cancer Investig J 2014; 3: 208-12.
5. Bhartiya R, Mallik M, Kumari N, Prasad BN.Evaluation of thyroid lesions by fine-needle aspiration cytology based on Bethesda system for reporting thyroid cytopathology classification among the population of South Bihar. Indian J Med Paediatr Oncol 2016; 37: 265-70.
6. H. M. E Hennawy, H. O. Abu Zaid, Imaad Bin Mujeeb, Eihab A. El Kahlout, El S. M. Bedair Accuracy of Fine Needle Aspiration Cytology of Solitary Thyroid Nodules in Tertiary versus Community Hospital http://dx.doi.org/10.4236/ss.2013.411096.
7. Handa U, Garg S, Mohan H, Nagarkar N. Role of fine needle aspiration cytology in diagnosis and management of thyroid lesions: A study on 434 patients. J Cytol 2008; 25: 13-7.
8. Chetna S. Diagnostic accuracy of fine needle aspiration cytology of thyroid and evaluation of discordant cases Journal of the Egyptian National Cancer Institute (2015) 27, 147–153.
9. Likhar KS, Hazari RA, Gupta SG, Shukla U. Diagnostic accuracy of fine needle aspiration cytology in thyroid lesions: A hospitalbased study. Thyroid Res Pract 2013; 10: 68-71.
10. Tatlıpınar A, Kartal İ (2015) The Evaluation of Thyroid Nodules. Thyroid Disorders Ther 4: 181. doi:10.4172/2167-7948.1000181.

Source of Support: None Declared
Conflict of Interest: None Declared