Original Research Article

Clinical study and management of patients of foreign bodies in larynx and tracheobronchial tree

Vasanti Vilasrao Patil[1*], Vikas Sudhakar Kulkarni[2], Veena V Kulkarni[3]

[1]Assistant Professor, Department of ENT, RCSM, Government Medical College, Kolhapur, Maharashtra, INDIA.
[2]Associate Professor, Department of ENT, Krishna institute of Medical Sciences and Deemed University, Karad, Maharashtra, INDIA.
[3]Director of V V ENT and endoscopy Hospital PVT ltd, Islampur, Maharashtra, INDIA.
Email: drvasantient@gmail.com

Abstract

The present study was undertaken to diagnose and manage laryngeal and tracheobronchial foreign bodies in a tertiary care center. This study included cases presenting with history of foreign body aspiration to emergency department, ENT department and cases with non responding respiratory tract infection from paediatric ward of the same Hospital. In the present study, 70 patients who had aspirated foreign bodies in their tracheobronchial tree were clinically studied and managed. A greater proportion of patients (73%) were under the age of 4 years. More than one radiological sign was seen in most of the patients. In this study the ratio of occurrence of foreign bodies in right main bronchus and left main bronchus was 1.18:1.

Key Words: Foreign body in larynx and tracheobronchial tree, rigid bronchoscopy, tracheobronchial angle, radiological signs.

***Address for Correspondence:**
Dr. Vasanti Vilasrao Patil, Assistant Professor, Department of ENT, RCSM, Government Medical College, Kolhapur, Maharashtra, INDIA.
Email: drvasantient@gmail.com
Received Date: 12/11/2017 Revised Date: 19/12/2017 Accepted Date: 03/01/2018
DOI: https://doi.org/10.26611/1016514

Access this article online	
Quick Response Code:	Website: www.medpulse.in
	Accessed Date: 14 January 2018

INTRODUCTION

Foreign body is an object or a substance, foreign to a location where it is found. There are two general classes, namely, exogenous including substances from outside the body and endogenous including those from within the body[1]. The subject of foreign bodies in air and food passages has always been a source of clinical interest. It was until 1897, when Gustav Killian in Germany performed the first bronchoscopy for the removal of foreign body[2]. Basic principles of management of patients with foreign bodies remain the same even today, except for the vast increase both qualitatively and quantitatively in the surgeon's armamentarium of endoscopes and forceps. Advances in anaesthesia techniques, availability of antibiotics, steroids have contributed to safety and efficacy of the procedure. Aspiration of a foreign body is a preventable accident. The National Safety Council of America has accepted foreign body inhalation as the commonest cause of accidental death in the home children less than six years of age[3].

MATERIAL AND METHODS

In the present study the total number of 70 cases of foreign bodies in larynx and tracheobronchial tree were investigated and managed. This retrospective study was carried out from Aug. 2006 to June 2009 covering total period of 34 months. The detailed proforma with special reference to history, clinical examination, investigations, management and complications was filled in. Complications occurring in the course of management were dealt with appropriately and relevant entries were made on proforma.. A thorough clinical examination was carried out with special reference to respiratory system. Routine investigations like estimation of Hb %, Total and Differential WBC Count, Urine for Albumin and Sugar was carried out. X-ray chest PA and lateral views were

How to cite this article: Vasanti Vilasrao Patil, Vikas Sudhakar Kulkarni, Veena V Kulkarni. Clinical study and management of patients of foreign bodies in larynx and tracheobronchial tree. *MedPulse International Journal of ENT.* January 2018; 5(1): 16-18. https://www.medpulse.in/ENT/

taken in inspiratory and expiratory phases. The films were carefully scrutinized for the presence of emphysema, collapse, mediastianal shift, pneumonitis, bronchopneumonia, radio-opaque foreign body. In cases of doubt, expert radiological opinion was sought for. The tracheobronchial angle was measured using Brown-Fisk method. The difference between right and left trancheobronchial angles measured[4,5].

RESULTS

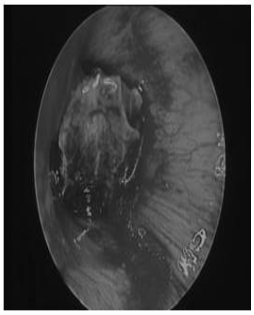

Figure 1

Figure 2

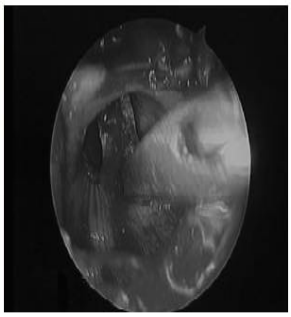

Figure 3

Figure 4

Legend

Figure 1: Foreign body in subglottis bnw; **Figure 2:** Foreign body in subglottis; **Figure 3:** Foreign held with forceps bnw; **Figure 4:** Jackfruit seed removed through tracheostomyr

Table 1: Radiological findings

Radiological Findings	No. Of Cases	Percentage
Emphysema	23	33%
Collapse	28	40%
Mediastinal Shift	19	27%
Bronchopneumonia	29	41%
Radio-Opaque Foreign Body	07	10%
No Pathology	16	23%

Table 2: Relation between difference in tracheobronchial angles and side of lodgement of foreign body

Diff. Of Tb Angle On Rt. And Lt. Side	No. of Cases With Percentage	FB On Rt. With % Out Of Total No Of FB On Rt.	FB On Lt. With % Out Of Total No Of FB On Lt.
3^0 TO 7^0	32 (54%)	13 (41%)	25 (93%)
MORE THAN 7^0	27 (46%)	19 (59%)	02 (7%)
Total	**59 (100%)**	**32 (100%)**	**27 (100%)**

Bronchoscopy was performed in few cases where clinical suspicion alone was strong, although investigation was not supportive leading to diagnostic bronchoscopy. Usually in such cases foreign body was central i.e. in trachea. Technique: The plan of management was decided as per the general condition of the patient. In our series PERORAL BRONCHOSCOPY was performed in each case. All patients wherein aspiration of foreign body was suspected were posted for bronchoscopy at the earliest. All procedures were carried out under general anaesthesia. Patients were preoxygenated with 100% oxygen for 5 minutes. Larynx and tracheobronchial tree was sprayed with 4% lignocaine either through Macintosh Laryngoscopy or through cricothyroid puncture. Foreign bodies were removed with the help of conventional forceps. Optical forceps facility was not available. Wherever required ventilation was carried out either through Jackson Rees Paediatric Circuit attached to ventilating bronchoscope or Sander's Jet Ventilation technique or MMV. Tracheostomy was performed to remove difficult foreign bodies in 2 cases. After complete removal of foreign body, a check bronchoscopy was done to detect any other foreign body and to access the extent of mucosal damage. The procedure was usually confined to less than 30 minutes. Postoperatively patient was kept under strict observation. Patients were discharged once their general condition was stabilized. Patients were followed up for a period of 3 months.

In present study 73% cases were below the age of 4 years. Children above the age of 4 years were 20% and adults (above the age of 12 years) were 7%. Positive history of aspiration was available in 79 % of cases in this study. However in 21% cases even after detailed history, the positive history of aspiration could not be elicited. In the present study patients presented with one or more of the following signs and symptoms: Cough, Breathlessness, Fever, Choking, Cyanosis, Vomiting, Dysphagia, Hoarseness, Stridor and thud. The commonest radiological findings were collapse, bronchopneumonia followed emphysema. More than one radiological sign was seen in most of the patients.

- Out of 59 cases, in 54% foreign bodies were removed from right main bronchus and in 46% foreign bodies were removed from left main bronchus.
- In this study the ratio of occurrence of foreign bodies in right main bronchus and left main bronchus was 1.18:1.

- Excluding laryngeal, tracheal and foreign bodies in both bronchi (in one patient) amounting total no. Of cases-11.

DISCUSSION

Proper mastication in children is established at the time of eruption of molars which completed around the age of 4 years. Infants and children have a natural desire to taste any new object by putting it into the mouth. **Paul G. Bunker,** who has studied the problem of foreign body aspiration in children, was forced to conclude that the dental factor is an important factor[6].

Age Incidence: Garbis Harboyan *et al* reports 87% cases below the age of 4 years[7]. In a similar study Marshall Strome found 82%[8], Rothman found 77%[9] and 74% in much larger series of Jackson and Jackson[1].

Symptoms: Positive history of aspiration was available in 79 % of cases in this study. In Rothman's series 87% of patients had positive history of aspiration but in some patients this positive history was only obtained retrospectively after removal of foreign body[8]. In this study in all 74% of cases presented with cough as a symptom. Cough was usually associated with breathlessness (96 %) and choking (46%). In Carluccio F *et al* study 73.9% patients were presented with cough, 51% patients had dyspnoea and 17.3% patients had fever[10]. In Cataneo AJ *et al* study, 68.3% patients had history of coughing, 54.9% patients had history of choking[11]. Decreased or absent air entry was the most common sign (90%) in present study. Commonest complication was pneumonia (14%) followed by bronchiectasis (4%) in the present study. In Harboyan *et al* study 2.5% patients had pneumonuia and 0.5% patients had bronchiectasis[7].

Radiology: The commonest radiological findings were collapse (40%), bronchopneumonia (40%) and emphysema (33%). Emphysema was obstructive in type in some cases who presented early and compensatory type in cases having collapse or pneumonitis of affected side. 23% patients in present study were radiologically normal because they presented very early or had small foreign bodies causing partial obstruction only; or with laryngeal or tracheal foreign bodies permitting equal air entry on both sides. Marshall Strome also reports 34% radiologically normal cases in his study[8]. According to Cataneo AJ *et al* study radiological findings were emphysema (17.1%), collapse (40.9%), radio-opaque foreign body (20.7%) and normal chest x-ray (21.3%)[11].

Site of foreign body: In this study the ratio of occurrence of foreign bodies in right main bronchus and left main bronchus was 1.18:1.In the largest series of Jackson and Jackson the ratio of occurrence of foreign bodies in right to left main bronchi was 1.82:[11]. In Garbis Harboyan series the ratio was 2.2:1[7]. In Rothman series the ratio was 1.02:1[9]. In Carluccio F *et al* series the ratio was 1.88:1[10].

CONCLUSION

For diagnosis of foreign bodies in air passage high index of suspicion is most essential. Mortality and morbidity associated with aspiration of foreign body in tracheobronchial tree can only be reduced if patient seeks medical aid early and is managed by those, skilled and experienced in the procedure of endoscopy. Careful vigilance is necessary before, during and after the procedure if we are to prevent, detect and treat fatal complications. Last but not least, a foreign body aspiration is a preventable accident. Education of parents and public at large will go a long way in reducing the incidence of foreign body aspiration in children.

REFERENCES

1. Jackson and Jackson: Broncho–oesophagology–W. B. Saunders Publications, Philadelphia – 1950.
2. Clerf L. H.: Historical aspects of foreign bodies in air and food passages – Annals of Oto – Rhino – Laryngology - 1952: 61: 5-17.
3. A. H. Maclean Ross- Foreign body inhalation – Journal of Royal College of Surgeons, Edinburgh – 1980: 25: 104-109
4. Hasan et al: Right lung collapse, a tantalising myth- Indian Journal of Oto – Rhino – Laryngology – 1992: 1: 164-168.
5. Hasan et al: Changes in tracheo-bronchial angles as a function of age – Indian Journal of Oto – Rhino – Laryngology – 1993: 2: 1-6.
6. Aberdeen S. D., Paul Bunker: Dental factors in foreign body problems, Annals of Oto – Rhino – Laryngology: 71: 1073: 1962.
7. Garbis Harboyan: Tracheobronchial foreign bodies, a review of 14 years experience – Journal of Laryngology – 1970: 84: 403 – 411.
8. Marshall Strome: Tracheobronchial foreign bodies, an updated approach – Annals of Oto – Rhino – Laryngology – 1977: 86: 849.
9. Rothman Bruce F.: Foreign bodies in larynx and tracheobronchial tree in children, a review of 225 cases - Annals of Oto – Rhino – Laryngology – 1980: 89: 434-436.
10. Carluccio F, Romeo R: Inhalation of foreign bodies: epidemiological data and clinical considerations in the light of a statistical review of 92 cases. Acta Otorhinolaryngol Ital. 1997 Feb; 17(1):45-51
11. Cataneo AJ, Cataneo DC, Ruiz RL Jr. Management of tracheobronchial foreign body in children. International Journal of Paediatric Surgery.2008 Feb; 24(2):151-6.

Source of Support: None Declared
Conflict of Interest: None Declared