Original Research Article

External vs endonasal dacryocystorhinostomy - A comparative study

Aruna Arumugam[1*], Samarapuri A[2], Yogeswari A[3], Malarvizhi R[4], Radhakrishnan M[5]

[1]Sr.Assistant Professor, Department of Ophthalmology, Government Royapettah Hospital and Government Kilpauk Medical College, Chennai, Tamil Nadu, INDIA.
[2]Associate Professor, Department of Ophthalmology, Chengalpet Government Medical College and Hospital, INDIA.
[3,4,5]Professor, Department of Ophthalmology, RIO-GOH, INDIA.
Email: aruna269@gmail.com

Abstract

Aim: To compare external and endonasal dacryocystorhinostomy (DCR) and to assess the surgical outcome and comfort levels of the patient in terms of pain and edema in the immediate post operative period. **Materials and Methods:** A prospective study was carried out on 100 patients, of whom 52 underwent external dacryocystorhinostomy and 48 underwent endonasal dacryocystorhinostomy at a tertiary care centre over a span of one year. 72 females and 28 males in the age group 18-55 were included in this study. All were diagnosed as dacryocystitis and all were primary DCRs The diagnosis of dacryocystitis was made clinically by the regurgitation test and lacrimal syringing test. Slit lamp examination was done to exclude diseases of the anterior segment. A Schirmers test to rule out dry eye, a diagnostic nasal endoscopy, hemogram, blood sugar, bleeding and clotting time, X-ray lacrimal sac region and Blood pressure recording were done. **Results and Conclusion:** Females had a higher incidence of dacryocystitis, when compared to males. Endonasal DCR was the preferred modality of surgery in the younger age group due to its cosmesis. The average operating time was found to be lesser in external DCR while bleeding was marginally higher in external DCR, than in endonasal DCR .The success rate was higher in the external group(95%)as against 89%in the endonasal group, while the comfort levels of the patient in terms of immediate post operative pain and edema was significantly better in the endonasal group.

Key Words: Dacryocystitis, dacryocystorhinostomy, endonasal, external.

***Address for Correspondence:**
Dr. Aruna Arumugam, Sr.Assistant Professor, Department of Ophthalmology, Government Royapettah Hospital and Government Kilpauk Medical College, Chennai, Tamil Nadu, INDIA.
Email: aruna269@gmail.com
Received Date: 18/07/2018 Revised Date: 09/08/2018 Accepted Date: 12/09/2018
DOI: https://doi.org/10.26611/1009733

Access this article online	
Quick Response Code:	Website: www.medpulse.in
	Accessed Date: 14 September 2018

INTRODUCTION

Dacryocystitis is an infection of the lacrimal sac, secondary to obstruction of the naso lacrimal duct at the junction of lacrimal sac. Dacryocystitis causes pain, redness and swelling over the inner aspect of the lower eyelid with associated epiphora. The acute phase is treated with oral antibiotics and anti edema measures while the definitive treatment of chronic dacryocystitis is dacryocystorhinostomy, which may be external or endonasal.

MATERIALS AND METHODS

This prospective comparative study was carried out on 100 patients, of whom 52 underwent external dacryocystorhinostomy and 48 underwent endonasal dacryocystorhinostomy at a tertiary care centre in Chennai over a year's span.

Selection Criteria: 100 patients (72 females and 28 males) were included in the study who were in the age group 16-60..None of them had any major systemic illness, like diabetes or hypertension. All were diagnosed as dacryocystitis and all were primary DCRs.

How to cite this article: Aruna Arumugam, Samarapuri, Yogeswari A, Malarvizhi R, Radhakrishnan M. External vs endonasal dacryocystorhinostomy- A comparative study. *MedPulse International Journal of Ophthalmology.* September 2018; 7(3): 42-45. https://www.medpulse.in/Ophthlmology/

Exclusion Criteria: Patients with canalicular and common canalicular obstruction, patients aged less than 16 years and more than 60 years and patients with suspicious lacrimal sac malignancies were excluded from the study.

Clinical evaluation: History and examination in detail was carried out in all cases of epiphora/discharge/swelling in the sac region. The diagnosis of dacryocystitis was made clinically by the regurgitation test , (punctual reflux of mucopurulent discharge on compression) and lacrimal syringing (simple or mucopurulent discharge through the opposite punctum). Medial canthal area assessment for inflammation, fistulae or swelling was done. Slit lamp examination was done to exclude diseases of the anterior segment. Other tests done were Schirmers test to rule out dry eye and a diagnostic nasal endoscopy to rule out nasal pathology.

Investigations done

Blood: Hemogram ,blood sugar ,bleeding and clotting time

Urine: Albumin, sugar and deposits

X-ray lacrimal sac region and

Blood pressure recording

Surgical Details And Post Operative Management: 52 patients underwent standard external dacryocystorhinostomy (DCR) and 48 patients underwent endonasal dacryocystorhinostomy. All patients were operated under local anesthesia, by different surgeons.

Standard External DCR- Procedure: After nasal packing and local infiltration anaesthesia using 2% lignocaine with adrenaline, curvilinear skin incision of 1.5-2 cm made about 5 mm from the medial canthus, just above the level of the medial canthal tendon. Orbicularis muscle was separated and Medial palpebral ligament was cut at its periosteal attachment and sac and anterior lacrimal crest were identified. Periosteum was elevated and laterally rotated along with the sac. Creation of ostium, with/without anterior ethmoidectomy - Osteotomy was done at the junction of the thin lacrimal and thick maxillary bone with the periosteal elevator and enlarged. Anterior and posterior flaps were created from the sac and nasal mucosa by 'H' shaped incisions and the anterior flaps were sutured using 5-0 catgut. Incision was sutured in layers after securing hemostasis and dressing was applied.

Endonasal DCR: After intranasal packing and infiltration anaesthesia using 2% lignocaine with adrenaline, a horizontal incision, about 10 to 15mm just anterior to the attachment of middle turbinate and in front of the uncinate process. was made. A second horizontal incision lower down commencing from the uncinate process at the level of the attachment of inferior turbinate was made and a vertical incision joining the two previous incisions was made. The mucosal flap was raised posteriorly and excised to expose the bone overlying the sac, which was removed. Medial wall of the sac, was incised vertically and then removed completely. Stenting was not done in any of our patients.

Post Operative Care: In both sets of patients, post operatively, nasal pack was removed after 4-6 hours and hemostasis confirmed. Oxymetazoline nasal drops to clear residual blood clots and keep nasal cavity moist was used and follow up syringing of nasolacrimal duct with antibiotic-steroid drops to minimize inflammation and granulation tissue was done.

OBSERVATION AND ANALYSIS

Verbal pain and edema score (0-3), where 0 represented nil pain/edema, 1-mild pain/edema, 2- moderate pain/ edema and 3 stood for severe pain /edema, was used to assess immediate post operative pain and edema.

Regular follow up of patients was done on day 1, 1 week, 1month, 3 months and 6 months. .

A successful outcome constituted both anatomic patency of the nasolacrimal duct and symptomatic relief.

The results were analysed.

Table 1: Age Wise Distribution Of Patients

AGE GROUP	%OF PATIENTS	
	Ext DCR	Endo DCR
16-30	7 (13.46%)	13 (27.08%)
31-40	15 (28.84%)	21 (43.75%)
41-60	30 (57.69%)	14 (29.16%)

Table 2: Sex Distribution

	Male	Female
External DCR	18(34.61%)	34(65.38%)
Endonasal DCR	10(20.83%)	38(79.16%)

Table 3: Laterality

	Right	Left
External DCR	31(59.61%)	21(40.38%)
Endonasal DCR	28(58.33%)	20(41.66%)

On the first and second follow up, i.e. on day 1 and end of the first week, all patients of the external DCR group had patent naso lacrimal ducts, while 1 patient of the endonasal group had mucopurulent regurgitation, and she was treated with meticulous antibiotic- steroid syringing on alternate days till duct became patent. At the end of the first month follow up, 51 (98.07%) of 52 patients of the external DCR group and 47(97.91%) of the endonasal group had patent nasolacrimal ducts, while 1 patient of the endonasal group was lost to follow up. On the 3 rd month follow up there were 2 drop outs each in both groups. Others were found to have patent ducts (94.23% - external DCR and 91.66% -endonasal DCR). At the end

of six months, 2 more were lost to follow up. 48 (94.23%) of the 52 of group 1 had patent ducts, while 2 patients of group 2 had blocked ducts giving an outcome percentage of 89.58% in the endonasal group. Both patients with blocked ducts showed fibrous adhesions on diagnostic endoscopy and were subjected to revision surgery. Regarding immediate post operative pain and edema (day 1), 37(71.15%) patients of group 1experienced a verbal pain and edema score of 2, while 12 (23.07%) patients gave a score of 3 and 3 (5.7%) were relatively pain free. In the endonasal group, almost all the patients had pain and edema score of less than 2, 12 (25%) patients gave a score of 1, and 29 (60.41%) gave a score of 0 and 1 (2.08%) gave a score of 2.

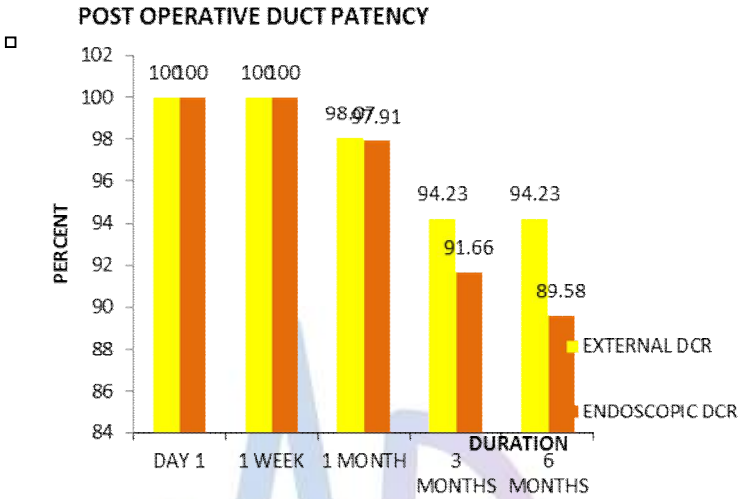

Figure 1:

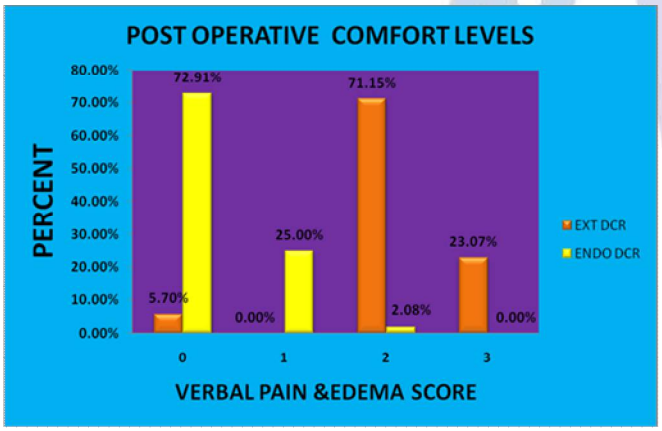

Figure 2:

Table 4: Post operative duct patency

End of 1 week	External DCR 52(100%)	Endoscopic DCR 48(100%)
END OF 1 MONTH	51(98.07%)	46(97.91%)
END OF 3 MONTHS	49(94.23%)	44(91.66%)
END OF 6 MONTHS	48(94.23%)	43(89.58%0

Table 5: Complications –intra and post operative complications

	EXTERNAL DCR	ENDONASAL DCR
Hemorrhage	2(3.84%)	-
Epistaxis	1(1.90%)	1(2.08%)
Csf leakage	-	-
scarring	1(1.90%)	-
Canalicular stenosis	-	-

Intraoperative bleeding was managed by adrenaline nasal packs. 2 patients with late ostial closure due to adhesions underwent revision surgery after release of adhesions.

Table 6: Comparative analysis

External DCR	Endonasal DCR
Exellent Outcome (90-95%)	85-90%
Cost Effective	Comparatively Expensive
Short Learning Curve	Steeper Learning Curve
Shorter Operating Time	Prolonged Operating Time
Bleeding, Pain And Edema More	Comparatively Less
External Scar Present	Cosmetically Acceptable
Revision Surgery Difficult	Easier
Bilateral Surgery Not Possible At Same Sitting	Possible
Not Possible In Acute Conditions	Possible

DISCUSSION AND RESULTS

- Females had a higher incidence of dacryocystitis, when compared to males.
- Dacryocystitis was more common on the right side.
- Endonasal DCR was the preferred modality of surgery in the younger age group due to its cosmesis.

- Bleeding was relatively higher in external DCR (5.76%), than in endonasal DCR (2.08%).
- The average operating time was found to be lesser in external DCR, averaging 30 minutes, while it ranged from 45 to 60 minutes in endonasal DCR.
- The success of the surgery was determined by a patent nasolacrimal duct on lacrimal irrigation and symptomatic relief to the patient. The success rates at the end of 6 months, was 94.23% for external DCR which compares favourably with
- Studies by R K Bansal *et al*, at the Department of Ophthalmology, Govt. Medical College, Chandigarh, with a success rate of 95% in external DCR and
- Comparative study of external and endonasal DCR, (IJO and Head and Neck Surgery, Vol 52, No 1/ Dec 99), with a success rate of 93% in external DCR.
- The success rates at the end of 6 months was 89.58% for endonasal DCR, which is slightly lower than that seen in studies conducted by
- Tsirbas and Wormald with a success rate of 95% and
- Comparative study of external and endonasal DCR, (IJO and Head and Neck Surgery,Vol 52, No 1/ Dec 99), with a success rate of 100% in endonasal DCR.
- This could be attributed to the fact that stents were not used in any of our patients and mucosal flaps were not sutured.
- A pre operative diagnostic nasal endoscopy goes a long way in improving the results of endonasal surgery.
- The comfort levels of the patient in terms of immediate post operative pain and edema (day 1),was better in the endonasal group (98%) when compared to the external group.

CONCLUSION

- Both procedures had comparable results, with external DCR scoring a higher success rate as against endoscopic DCR.
- The comfort levels of the patient in terms of immediate post operative pain and edema (day 1), was significantly better in the endonasal group when compared to the external group.

However, a systematic and holistic approach is mandatory in all cases of watering, and the mode of surgery is tailored to the patient's individual needs and the surgeons expertise.

REFERENCES

1. Dipak Ranjan Nayak, Manipal Manual Of Endoscopic Sinus Surgery, 1st edition, 2008, 43-50, 68-71, 109-112
2. Jakobeic, Principles And Practice Of Ophthalmology, 2 nd Edition, Vol 4, Lids And Orbit, 3550-3564
3. Smith's Ophthalmic Plastic And Reconstructive Surgery, 2 nd Edition, 1998, 13-25
4. Endoscopic Sinus Surgery- Levine And May
5. Wormald, Peter John, Endoscopic Sinus Surgery- Anatomy, 3 Dimensional Reconstruction And Surgical Technique, 2 nd edition,143-153
6. Anatomical Principles Of Endoscopic Sinus Surgery: A Step By Step Approach, RenukaBradoo, 1st edition, 2005, 59-83
7. Rupinder K Ranga, S P S Yadav, Advin, Endonasal DCR: Is It An End Of The Road For External DCR? , JIMA 2008; 106: 228-31
8. Management of Acquired Nasolacrimal Duct Obstruction: External And E ndonasal DCR –Is There A Third Way? ,British Journal Of Ophthalmology, 2009; 93: 1416-9
9. Comparative Study of External And Endonasal DCR, Indian Journal Of Otolaryngology And Head And Neck Surgery, Vol 52, Number 1, December 1999.
10. Management of Acquired Nasolacrimal Duct Obstruction: External and Endonasal DCR, British Journal of Ophthalmology, 2009, 93:1416-1419.

Source of Support: None Declared
Conflict of Interest: None Declared