Original Research Article

Anatomical and congenital anomalies of liver and gallbladder: Its embryogenesis and clinical implications

Kalyan Chakravarthi Kosuri[1*], Siddaraju KS[2], Venumadhav Nelluri[3]

[1]Associate Professor, Department of Anatomy, Varun Arjun Medical College, Banthra-Shajahanpur, Uttar Pradesh, INDIA.
[2]Assistant professor, Department of Anatomy, KMCT Medical College, Manassery, Calicut, Kerala, INDIA.
[3]Assistant professor, Department of Anatomy, Melaka Manipal Medical College (MMMC), Manipal University, Manipal, and Karnataka, INDIA.
Email: kalyankosuric@gmail.com

Abstract

Background: The congenital anomalies of biliary tract especially liver and gallbladder are rare, preoperative knowledge of biliary tract variant is important for surgical planning and reduce postoperative complications. **Aim:** Accordingly the aim of this study was designed to evaluate the prevalence of congenital variations of liver and gallbladder. **Materials and Methods:** This study was carried out on routine human cadaveric dissection of abdomen (including dissected cadaveric specimens) conducted for medical undergraduates; anatomical and congenital variations of liver and gallbladder were observed. Photographs of the anatomical and developmental variations were taken for proper documentation. **Results:** Agenesis of caudate and quadrate lobes, absent of fissure for ligamentum teres and absent of fissure for ligamentum venosum were found in one specimen. Incomplete duplication of caudate and quadrate lobes with unusual abnormally elongated caudate process was found in one specimen. Abnormally placed gallbladder existing with elongated left lobe of liver was found in three specimens. Cystic arteries were noted absent and gall bladder was supplied by the liver parenchymal arterial vessels in all cases of complete and incomplete intrahepatic gall bladder noted. **Conclusion:** Awareness of such variations could be important for surgeons performing liver transplantation, tumor resection, and laparoscopic cholecystectomy and other radiological procedures to avoid possible complications and allows successful modern surgeries on hepatobiliary system.

Key Words: Agenesis, cholecystectomy, cholelithiasis, ductus venosus, intrahepatic gall bladder, liver transplantation.

***Address for Correspondence:**
Dr. Kosuri Kalyan Chakravarthi, Associate professor, Department of Anatomy, Varun Arjun Medical College, Banthra-Shajahanpur, Uttar Pradesh, INDIA.
Email: kalyankosuric@gmail.com
Received Date: 10/10/2019 Revised Date: 16/11/2019 Accepted Date: 22/12/2019
DOI: https://doi.org/10.26611/10011238

Access this article online	
Quick Response Code:	Website: www.medpulse.in
	Accessed Date: 26 December 2019

INTRODUCTION

The liver is the largest gland of the human body, occupying the right hypo-chondrium, the greater part of the epigastrium, and extending into left hypochondrium as far as left lateral line of the upper abdominal cavity. It consists of exocrine part secrets bile and endocrine part liberates glucose from the glycogen, most of the plasma proteins and heparin, directly in to the blood stream. The gallbladder is a pear-shaped, hollow structure located on the under surface of the right lobe of liver and concentrate and store bile produced by the liver. Liver consists of major fissures, fissure for ligamentum venosum and fissure for ligamentum teres are important landmarks for interpreting the lobar anatomy and locating the liver lesion. Anatomically the liver is divided in to right and left lobes by the reflection of the falciform ligament on the anterior surface, the fissure for ligamentum teres on the inferior surface, and the fissure for the ligamentum

How to cite this article: Kalyan Chakravarthi Kosuri, Siddaraju KS, Venumadhav Nelluri. Anatomical and congenital anomalies of liver and gallbladder: Its embryogenesis and clinical implications. *MedPulse – International Journal of Anatomy.* December 2019; 12(3): 91-96. http://www.medpulse.in/Anatomy

venosum on the posterior surface. Caudate and quadrate lobes belong to the anatomical right lobe of liver. Caudate lobe belong to the anatomical right lobe of liver but functionally part of left lobe as it receives blood supply from left branch of hepatic artery and portal vein and delivers bile to left hepatic duct. [1] Caudate lobe lies on the posterior surface of liver bounded on the right by vena caval groove, on the left ligamentum venosum, above posterior-superior border of liver and below by porta hepatis. Knowledge of lobe and fissure variations in the liver is of immense clinical and surgical importance. [2] The absence of normal fissures and lobes or the presence of accessory lobes and fissures might lead to confusion on a radiological diagnosis of a liver disorder. [3] To ensure safe and successful hepatic surgery a sound knowledge of biliary anatomy is essential in tumor resection and partial hepatectomy, liver transplantation, laparoscopic cholecystectomy. Accordingly, this study was aimed to evaluate the hepatic and biliary anatomical and congenital variations.

MATERIALS AND METHODS

This study was carried out on routine human cadaveric dissection of abdomen (including dissected cadaveric specimens) conducted for medical undergraduates at Varun Arjun medical college- Banthra,-UP, KMCT Medical College, Manassery- Calicut and Melaka Manipal Medical College-Manipal. Anatomical and congenital variations of liver and gallbladder were observed. Photographs of the anatomical and congenital variations were taken for proper documentation.

RESULTS

Out of 62 human cadavers (including dissected cadaveric specimens) irrespective of age and sex, dissected during the medical undergraduates teaching purpose, the following congenital variations of liver and gallbladder were noted-

Case-I: Complete intrahepatic gall bladder existing with fused quadrate lobe with left lobe of liver was found in one specimen (Fig-1).

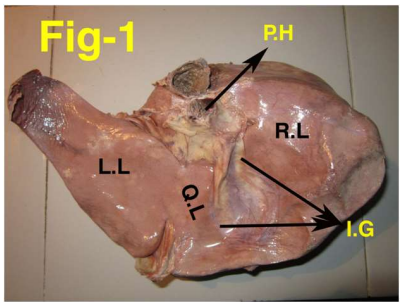

Figure 1: Showing complete intrahepatic gall bladder existing with fused quadrate lobe with left lobe of liver

I.G - complete Intrahepatic Gall bladder; L.L - Left lobe of liver; R.L - Right lobe of Liver; Q.L –Quadrate lobe of Liver; P.H – Porta Hepatis.

- Non peritoneal groove for inferior vena cava was located at the superior surface of the liver was noted.
- Round shaped non peritoneal fissure the Porta hepatis was located immediately below the groove for inferior vena cava at the posterior surface of the liver was noted.

Case-II: Agenesis of quadrate lobe, absent of fissure for ligamentum teres with incomplete intrahepatic gall bladder was found in one specimen (Fig-2).

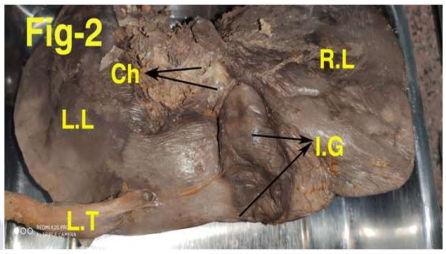

Figure 2: Showing agenesis of quadrate lobe, absent of fissure for ligamentum teres with incomplete intrahepatic gall bladder with cholelithiasis.

I.G - Incomplete intrahepatic Gall bladder; Ch – Cholelithiasis (stones in the gallbladder); L.T- Ligamentum Teres; L.L - Left lobe of Liver; R.L - Right lobe of Liver;

Case-III: Incomplete intrahepatic gall bladder with cholelithiasis was found in one specimen (Fig-3 and Fig-3a).

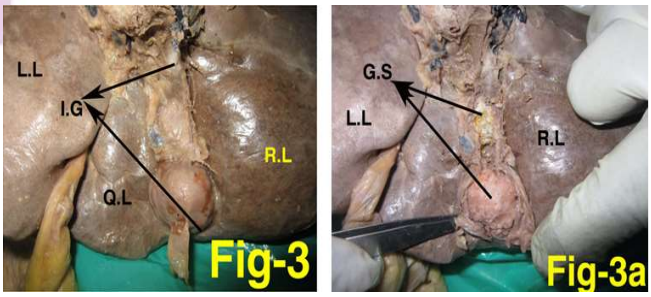

Figure 3: Showing Incomplete intrahepatic gall bladder with cholelithiasis; Figure 3a: Showing Incomplete intrahepatic gall bladder with cholelithiasis

I.G - Incomplete intrahepatic Gall bladder; L.L - Left lobe of Liver; R.L - Right lobe of liver; Q.L –Quadrate lobe of Liver;

Case-IV: vertical fissure in the caudate lobe (incomplete duplication of caudate lobe) with unusual thick band of hepatic tissue was attached to the gallbladder was found in one specimen (Fig-4).

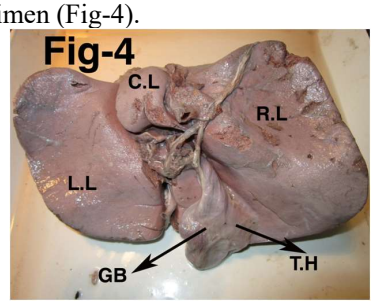

Figure 4: Showing incomplete duplication of caudate with unusual thick band of hepatic tissue attached to the gallbladder

G.B- Gall Bladder; T.H- Thick band of Hepatic tissue; L.L - Left lobe of Liver; R.L - Right lobe of Liver; C.L- Caudate lobe of Liver;

Case-V: Incomplete intrahepatic gall bladder with incomplete duplication of caudate lobe was found in one specimen (Fig-5).

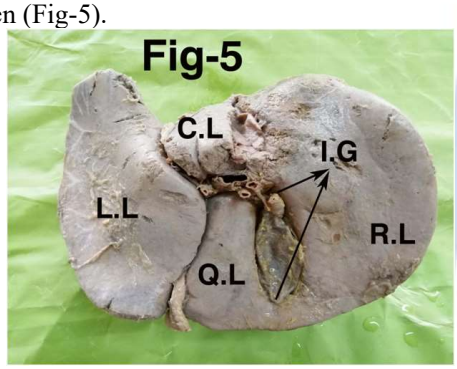

Figure 5: Showing Incomplete intrahepatic gall bladder with incomplete duplication of caudate

I.G - Incomplete intrahepatic gall bladder; L.L - Left lobe of liver; R.L - Right lobe of liver; C.L- Caudate lobe of Liver with vertical fissure; Q.L –Quadrate lobe of Liver;

Case-VI: Incomplete duplication of caudate and quadrate lobes with abnormally elongated caudate process forming roof of the gallbladder fossa was found in one specimen (Fig-6).

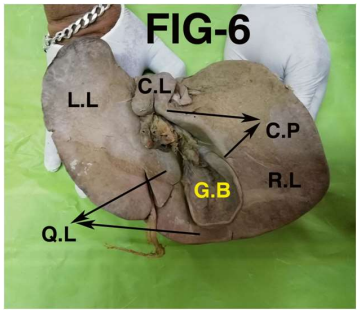

Figure 6: Showing Incomplete duplication of caudate and quadrate lobes with abnormally elongated caudate process

C.L- Incomplete duplication of Caudate Lobe of Liver; Q.L – Incomplete duplication of Quadrate lobe of Liver; C.P- Abnormally elongated Caudate Process; L.L - Left lobe of liver; R.L - Right lobe of liver;

Case-VII: Abnormally positioned gallbladder existing with large left lobe (nearly as large as its right) and fused quadrate lobe with left lobe of liver was noted in three specimens (Fig-7 and Fig-8).



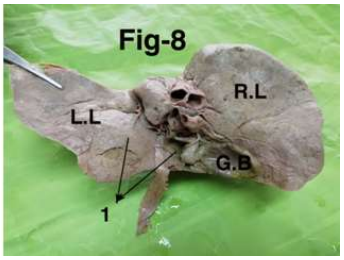

Figure 7: Showing abnormally located gallbladder; **Figure 8:** Showing absence of fissure for ligamentum teres, abnormally located gallbladder existing with fused quadrate lobe with left lobe of liver;

Fused quadrate lobe with left lobe of liver; L.L - Left lobe of liver; R.L - Right lobe of liver; G.B- Transversely located Gallbladder

Case-VIII: Agenesis of caudate and quadrate lobes, absent of fissure for ligamentum teres and absent of fissure for ligamentum venosum was found in one specimen (Fig-9).

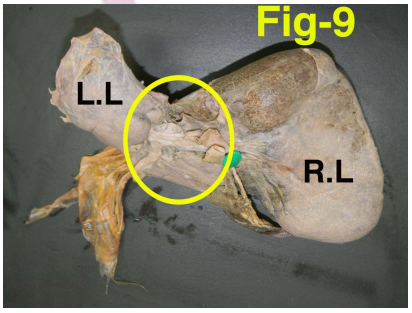

Figure 9: Showing agenesis of caudate and quadrate lobes, absent of fissure for ligamentum teres and absent of fissure for ligamentum venosum

L.L - Left lobe of liver; R.L - Right lobe of liver; Marked circle - Showing agenesis of caudate and quadrate lobes, absent of fissure for ligamentum teres and absent of fissure for ligamentum venosum;

Case-IX: Agenesis of caudate and quadrate lobes with vertically elongated leaf like projection of left lobe of liver was found in one specimen (Fig-10).

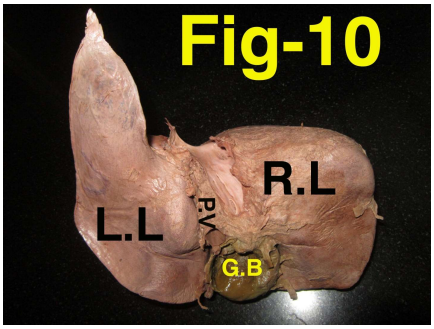

Figure 10: Showing Agenesis of caudate and quadrate lobes with vertically elongated leaf like projection of left lobe of liver

L.L - elongated leaf shaped Left lobe of liver; R.L - Right lobe of liver; G.B- Gallbladder; P.V- Portal Vein;

Cystic artery was absent and gall bladder was supplied by the liver parenchymal arterial vessels in all cases of complete and incomplete intrahepatic gall bladder.

DISCUSSION

During the 4th week of embryonic life the liver and its duct system develop as a hepatic bud from the ventral wall of the endoderm of foregut. The hepatic bud enlarges and divides in to a large cranial part pars hepatica and caudal small part pars cystica. The pars hepatica grows ventrally and reaches the septum transversum where it bifurcates into right and left branches. Each branch gives rise to solid plates of proliferating hepatic cells known as hepatic cylinders. These cylinders anastomose with one another and form the liver parenchyma and the mesenchyme of the septum transversum persists as the fibro-areolar stroma of the liver. The umbilical and vitelline veins present in the septum transversum broke up to form the sinusoids of liver. Probably hepatic cylinders persist as physiological right and left lobs of the liver. Congenital malformations of liver are absence of segments, absence of lobes, deformed lobes, smaller lobes, and one or more accessory lobes or fissures, and atrophy of lobes. Caudate anatomy is complex, because of its own vascularisation and biliary drainage and may cause difficulties in the interpretation of cross sectional images. According to Dodds *et al*. during second trimester the ductus venosus rotates rightward as the liver enlarges, so that a small portion of the liver becomes inserted behind the mesentery for the ductus venosus which gives rise to caudate lobe of liver. [4] Agenesis of caudate lobe noted in our study may be due to failure of transfer of small portion of liver tissue behind the mesentery for the ductus venosus. Different shapes and fissures of caudate lobes, abnormal position of caudate process have been noted and reported in the past.[5, 6, 7] To the best of our knowledge, incomplete duplication of caudate lobe with unusual abnormally located caudate process and gallbladder (Fig-6) noted in our study was not cited in modern medical literature. Incomplete duplication of caudate lobe noted in our study may be due to failure of separation from the main caudate lobe during second trimester of development which results in the formation of vertical fissures. Functionally, liver is essentially a segmental organ, the caudate lobe alone represents segment I. The presence of additional lobes and fissures or the absence of normal lobes and fissures might lead to confusion during surgery or clinical diagnosis, safe caudate lobe resection is still a major challenge, thus anatomical and developmental variations of the caudate lobe and its process found in our study is very essential for better surgical approach and outcome. The quadrate lobe lies on the inferior surface of liver bounded on the right side by the fossa for gallbladder, on the left by the fissure for ligamentum teres, above by the porta hepatis below by the inferior border of the liver. Nayak *et al*. reported in their study that quadrate lobe and fissure for ligamentum teres were absent. [8] In our study agenesis of caudate and quadrate lobes existing with absent of fissure for ligamentum teres and absent of fissure for ligamentum venosum was noted (Fig-9). Shilpi GD *et al*. reported absent of quadrate lobe. [9] Using the Counaud nomenclature quadrate lobe represents segment IVb, duplication of quadrate lobe with incomplete duplication of caudate lobe (Fig-6), agenesis of quadrate lobe with agenesis of caudate lobe (Fig-9 and Fig-10), complete intrahepatic gallbladder and fusion of quadrate lobe with left of liver noted (Fig-1) in our study not reported in the past. Combination of such multiple congenital variations noted in our study may be of great important in preventing confusion in radiological as well as surgical diagnosis and will help for successful modern surgeries on hepatobiliary system. Gall bladder and cystic duct develops from the pars cystica of hepatic bud. In reptiles and marsupials gall bladder is intrahepatic in location, where as in human being it is intrahepatic during the embryologic development it becomes extra hepatic during the second month of gestation. An ectopic gallbladder is a developmental or congenital abnormality in which the gallbladder is not located in its normal gallbladder fossa attached to the liver. Biliary anatomy is very rare occurs in approximately 0.1%–0.7% of people. [10] Intrahepatic gallbladder (Fig-1, Fig-2 Fig-3, and Fig-3a) noted in our study may be due to positional arrest during development. The gallbladder can be situated in a variety of anomalous positions the most common ectopic locations are intrahepatic, beneath the left lobe of the liver, transversely oriented, extremely rare cases present within the falciform ligament and suprahepatic. [11] In our study abnormally positioned gallbladder (transversely oriented gallbladder, a fixed gallbladder to the liver by a thick band of hepatic tissue) existing with large left lobe

(nearly as large as its right) and fused quadrate lobe with left lobe of liver was noted in three specimens (Fig-4, Fig-7 and Fig-8). Such large left lobes may cause pain in the epigastrium, may be misdiagnosed as splenomegaly, distension of the splenic flexure of the colon, gastrooptosis, hydatid cyst or sarcoma of liver. Such hepatic abnormality when associated with biliary variations may leads to the increased risk in the diagnosis and management of hepato biliary diseases.[12, 13] An intrahepatic gallbladder is one partially or completely embedded within the liver parenchyma, Mohammad F Ali *et al*. reported a case of intrahepatic gallbladder with a cholecystogastric fistula. [14] Very few cases of intrahepatic gallbladder have been reported in medical literature, agenesis of caudate and quadrate lobes of liver with complete intrahepatic gall bladder found in our study have not been cited in modern literature. Unrecognition of such congenital anatomical variations by the surgeon during liver transplantation or tumor resection can leads to postoperative bile leakage. *Cholelithiasis* refers to the presence of gallstones in the gallbladder, intrahepatic gallbladder *with cholelithiasis* leads to increased risk of pathology. Common hepatic duct obstruction caused by extrinsic compression from an impacted stone in the cystic duct or infundibulum of the gallbladder or inflamed gallbladder may leads to Mirrizi's syndrome. Falk V *et al.* reported a case of complete intrahepatic gallbladder with acute cholecystitis (inflammation of the gallbladder) in a young female patient. [15] Chandrasekar G *et al*. reported a clinical case of cholelithiasis in an intrahepatic gallbladder. [16] In our study cholelithiasis in an incomplete intrahepatic gall bladder with unusual agenesis of quadrate lobe was found. In intrahepatic gallbladder the degree to which the gallbladder is embedded within the liver parenchyma poses a diagnostic challenge can effects surgical approach, it is further complicated with cholelithiasis. Hence knowledge of such biliary congenital abnormalities should be kept in mind for the surgeon and the radiologist when planning for the different preoperative surgical approaches. Gall bladder is mainly supplied by cystic artery which is derived from right branch of hepatic artery. During an early embryonic period, the extra hepatic biliary system arises from endodermal diverticulum from the terminal part of foregut, which carries a rich supply of vessels from the aorta, coeliac trunk and superior mesenteric artery. Later most of these vessels are absorbed, leaving in place the mature vascular system. As the pattern of absorption is highly variable, it is not unusual for the cystic artery and its branches to derive from any other artery in the vicinity. [17] Multiple cystic arteries, short cystic arteries, double cystic arteries, cystic artery originating from gastro duodenal artery, from the liver parenchyma, from the left hepatic artery have been reported in the literature. [18, 19] Cystic arteries were noted absent and gall bladder was supplied by the liver parenchymal arterial vessels in all cases of complete and incomplete intrahepatic gall bladder noted in our present study, such congenital anatomic variants increase the risk of biliary or arterial injuries during surgery if unrecognized by the surgeon, subsequently, leading to a bile leakage or hemorrhage. The reported incidence of conversion to open surgery because of blood vessel injuries is approximately 0%-1.9% during laparoscopic cholecystectomy, and its mortality is about 0.02%. [20, 21] Thus a detailed preoperative evaluation of hepatobiliary vascular and its anatomy is mandatory to reduce complications during hepatobiliary surgery.The porta hepatis is the central non peritoneal transverse fissure on the inferior surface of the liver that separates the caudate and the quadrate lobes. It acts as a gateway for entry or exit for several *important* structures including the portal vein, the hepatic artery, the hepatic nervous plexus, the hepatic ducts and the lymphatic vessels. Hepatic surgery requires comprehensive knowledge of structures passing through porta hepatis. Transverse, anteroposterior diameter and total circumference of porta hepatis, variation of structures in the porta hepatis have been published in the literature but very rare and unusual location and shape of porta hepatis noted in our study not been cited n the modern medical literature (Fig-1). Sound knowledge of such congenital anatomical variation can reduce complications during invasive procedures like percutaneous drainage catheter placement, balloon dilatation, stenting, and coil embolization.

CONCLUSION

Hepato biliary multiple congenital variations like agenesis and duplication of caudate and quadrate lobes absent of fissure for ligamentum teres and fissure for ligamentum venosum, absent of cystic artery, intrahepatic gallbladder, abnormally positioned gallbladder, abnormally elongated caudate process noted in our study were not cited in modern medical literature. Such anatomical and congenital variations knowledge is immensely important because of its implications in liver transplantation tumor resection, biopsy, and laparoscopic cholecystectomy and other radiological procedures. Awareness of normal and variant hepato biliary anatomy and their recognition allows proper intra-operative planning to avoid and reduce possible postoperative complications.

REFERENCES

1. McMinn RMH. Vast's Anatomy-regional and applied. 8th edn. Churchill Livingstone 1990: 346.
2. Joshi SD, Joshi SS, Athavale SA. Some interesting observations on the surface features of the liver and their clinical implications. Singapore Med J. 2009; 50:715–719.
3. Fitzgerald R, Hale M, Williams CR. Case report: accessory lobe of the liver mimicking lesser omental lymphadenopathy. Br J Radiol. 1993; 66:839–841.
4. Dodds WJ, Erickson SJ, Taylor AJ, Lawson TL, Stewart ET. Caudate lobe of the liver: anatomy, embryology, and pathology. Am J Roentgenol. 1990; 154(1):87-93.
5. Chavan NN, Wabale RN. Morphological study of caudate lobe of liver. Indian Journal of Basic and Applied Medical Research. 2014; 3 (3): 204-211.
6. Sahni D, JitI, Sodhi L. Gross Anatomy of the caudate lobe of the liver. J Anat. Soc. India2000; 49(2): 123- 126.
7. Seyed HA, Hassan A. Coexistence of multiple anomalies in the hepatobiliary system. Anat Cell Biol 2012; 45:62-65.
8. Nayak SB, Mishra S, George BM, Shetty SD, Kumar N, Guru A, Rao SS, Aithal A. A peculiar liver with surgically and radiologically important variations: a case report. Anat Cell Biol. 2013; 46(1):82–84.
9. Shilpi GD, Seema D, Surajit G. Absent quadrate lobe of liver: anatomical and clinical relevance. Int J Anat Var. 2016; 9: 53–54.
10. Chowbey PK, Wadhwa A, Sharma A, *et al*. Ectopic gallbladder: laparoscopic cholecystectomy. Surg Laparosc Endosc Percutan Tech. 2004; 14:26–8.
11. Rafailidis V, Varelas S, Kotsidis N, *et al*. Two congenital anomalies in one: an ectopic gallbladder with phrygian cap deformity. Case Rep Radiol. 2014; 2014:1–4.
12. Sangeeta M, varalakshmi KL, Shilpa N. A study of the morphometry of the liver. Indian journal of applied research. 2014; 4:441-443.
13. Sharmila aristotle. Morphological study of anomalies of lobes and segments of human liver; int j pharm bio sci. 2016; 7: 810 - 815.
14. Ali MF, Friedel D, Levin G. Two anomalies in one: a rare case of an intrahepatic gallbladder with a cholecystogastric fistula. Case Rep Gastroenterol. 2017; 11:148–54
15. Falk V, Low G, Bigam D, Sandha G. Acute acalculous cholecystitis of an intrahepatic gallbladder causing Mirizzi's syndrome. BMJ Case Rep. 2018 Apr 13; 2018 [PMC free article]
16. Chandrasekar G, Nagappa V. Cholelithiasis in an intrahepatic gallbladder. Int Surg J. 2017; 4:3177-9.
17. Vishnumaya G, Bhagath KP, Vasavi RG, Thejodhar P. Anomalous origin of cystic artery from gastroduodenal artery – A case report. Int J Morphol. 2008; 26: 75–76.
18. Andall RG, Matusz P, Plessis Mdu, Ward R, Tubbs RS, Loukas M. The clinical anatomy of cystic artery variations: a review of over 9800 cases. 2016 Jul; 38(5):529-39.
19. You-Ming Ding, Bin Wang, Wei-Xing Wang, Ping Wang, Ji-Shen Yan. New classification of the anatomic variations of cystic artery during laparoscopic cholecystectomy. World J Gastroenterol 2007 November 14; 13(42): 5629-5634.
20. Thompson JE, Bock R, Lowe DK, Moody WE. Vena cava injuries during laparoscopic cholecystectomy. Surg Laparosc Endosc 1996; 6: 221-223
21. Deziel DJ, Millikan KW, Economou SG, Doolas A, Ko ST, Airan MC. Complications of laparoscopic cholecystectomy: a national survey of 4,292 hospitals and an analysis of 77,604 cases. Am J Surg 1993; 165: 9-14.

Source of Support: None Declared
Conflict of Interest: None Declared