

# Role of ultrasonic bone surgery device (piezosurgery®) in harvesting intraoral autogenous bone graft – A case report

Pooja M. Pharne<sup>1\*</sup>, Dinesh Hingorani<sup>2</sup>, Ulhas S. Mali<sup>3</sup>, Smita Vitthal Patil<sup>4</sup>

{<sup>1</sup>Assistant Professor, Department, Public Health Dentistry}, {<sup>3</sup>Associate Professor, Department of General Pathology}, {<sup>4</sup>Assistant Professor, Department of Physiology}, B.V.D.U. Dental College and Hospital, Sangli, Maharashtra, INDIA.

<sup>2</sup>Professor, Department of Periodontology, Dr. D.Y. Patil Dental College and Hospital, Pune, Maharashtra, INDIA.

Email: [drpoojapharne@gmail.com](mailto:drpoojapharne@gmail.com)

## Abstract

Piezosurgery® is a sophisticated ultrasonic device (Mectron, Italy) invented by Dr. Tomaso Vercellotti. Present study was conducted to see the efficacy and safety of ultrasonic bone surgery device in harvesting intraoral autogenous bone graft and to compare it with manual and rotary instruments. It is concluded that piezosurgery is very easy and safe to use for harvesting intraoral autogenous bone graft as compared to manual and rotary instruments.

**Keywords:** Bone surgery with ultrasound (Piezosurgery®), bone harvesting, physical cavitation phenomenon, microvibration.

## \*Address for Correspondence:

Dr. Pooja M. Pharne, Assistant Professor, Department, Public Health Dentistry, B.V.D.U. Dental College and Hospital, Sangli, Maharashtra, INDIA.

Email: [drpoojapharne@gmail.com](mailto:drpoojapharne@gmail.com)

Received Date: 04/01/2015 Revised Date: 18/11/2015 Accepted Date: 10/10/2016

## Access this article online

Quick Response Code:	Website: <a href="http://www.medpulse.in">www.medpulse.in</a>
	DOI: ---

## INTRODUCTION

Pohlman in 1950 was the first to apply ultrasound in humans for the treatment of neuropathic pain and myalgia<sup>1</sup>. In the same year Maintz also published the first study pointing out the beneficial effects of ultrasound upon bone healing<sup>2</sup>. In 1952, it was first used in dentistry, specifically for preparing dental cavities. Piezosurgery® is a sophisticated ultrasonic device (figure 1) (Mectron, Italy) introduced in medical practice in 1998 for different procedures applied to hard tissues, like periodontal surgery, periapical surgery<sup>3,4</sup>, removal of impacted tooth, implant surgery for facilitating bone ridge expansion or in bone regeneration techniques<sup>5,6</sup> and inferior dental nerve

lateralization and transpositioning<sup>7</sup>. This device was invented by Dr. Tomaso Vercellotti, designed to cut or grind the bone but not damage the adjacent soft tissue and with the purpose of securing improved precision and safety in bone harvesting and other bone surgeries compared with the manual and rotary instruments. The mechanism of this device is based on the 'Piezo effect' first described by French physicists Jean and Marie Curie in 1880<sup>8</sup>.

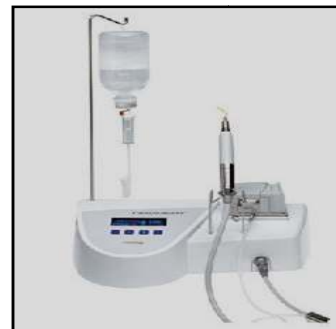

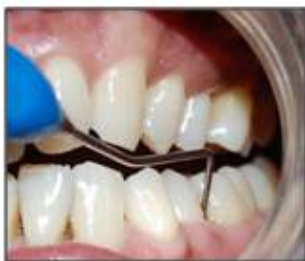Figure 1: Piezosurgery device

The device used in our study operates at a frequency of 25-29 kHz, with an advanced oscillation control module that introduces pauses in the high-frequency vibrations.

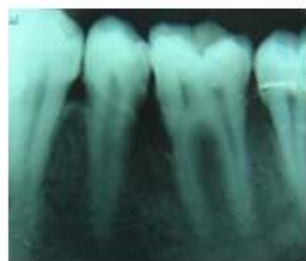These pauses help to avoid heating of the bone and maintain optimum sectioning capacity. The amplitude of the micro vibrations has to be kept in the range of 60-210  $\mu\text{m}$ , corresponding to a handpiece power rating of 5 W<sup>9</sup>. The Piezosurgery® device offers three specific therapeutic features attributable to the microvibrations and to specific modulation of the ultrasound frequency. Firstly, it allows micrometric sectioning, offering superior precision in cutting and with no bone loss. Secondly, the instrument selectively sections mineralized structures, without damaging the adjacent soft tissues, which remain intact even in the case of accidental contact with the device. Lastly, the physical cavitation phenomenon produced by the device ensures less bleeding<sup>10</sup>.

### Clinical case

A 32 year old male patient reported to Department of Periodontology and Oral Implantology with chief complaint of pain in lower left posterior region of the jaw with no relevant medical history. Clinical and radiographic examination was done and patient was diagnosed to be chronic generalized gingivitis with localized periodontitis of 35, 36 region with 8 mm pocket. All necessary investigations were carried out. Thorough scaling and root planning (SRP) was done and patient was recalled after 15 days. Even after SRP, pocket depth was found to be 8 mm (figure 2) and intraoral periapical radiograph (IOPA) revealed angular defect (figure 3). Hence we decided to proceed with surgical intervention by harvesting intraoral autogenous bone graft from symphysis region with the help of piezosurgery device and grafting (placing) it in between 35, 36 region.



**Figure 2:** Preoperative view showing 8 mm of periodontal pocket



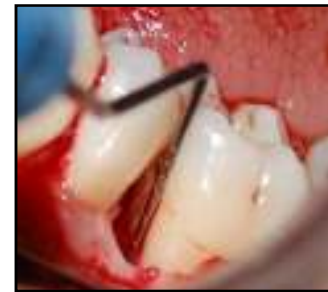**Figure 3:** Preoperative IOPA showing angular defect between 35, 36 region

A pre-operative dental panoramic tomograph was taken to confirm adequacy of mental bone apical to the roots of the patient's lower incisors to harvest intraoral autogenous bone graft. There is a chance of an increased incidence of altered sensation of lower incisors after harvesting bone graft from symphyseal region<sup>11</sup>. The same was explained to the patient and consent was taken.

### Procedure

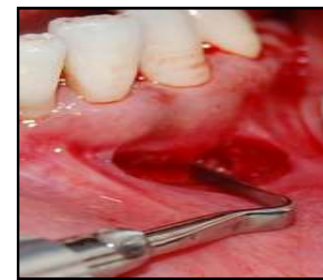A broad based full mucoperiosteal flap was raised at the recipient site (35, 36 region) to confirm the size of bone

graft that was necessary. Thorough degranulation and SRP was done. After probing 5 mm bone defect was seen (figure 4).



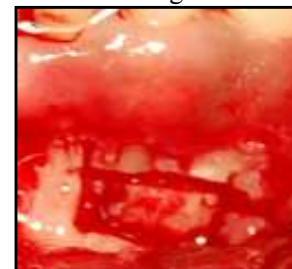
**Figure 4:** Probing the defect-5mm

A horizontal linear incision was made from lower right canine to lower left canine just apical to the mucogingival junction. The mucosa and mentalis muscle were lifted from the bone using a periosteal elevator. The lower border of the mandible was identified and the mentalis was reflected to just short of the lower border in order to avoid 'witches chin' which is a possible complication of this technique<sup>12</sup>. The apices of the lower incisors were identified and the initial cut into the bone was made 5mm below to the apices of the incisors with the help of piezosurgery device<sup>11,12</sup> (figure 5).



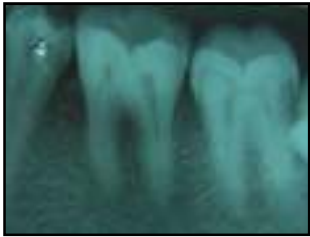**Figure 5:** Initial bonecut with UBS device

The outline of the bone block was completed (figure 6). The aim was to harvest a cortico cancellous block. Copious chilled isotonic saline irrigant was used to counter the heat generated by the blade tip. Piezosurgery device has depth marker. A check was made to ensure that the cut is through the cortical bone and into the cancellous bone and the bone graft was harvested.



**Figure 6:** Donor site preparation

The chin wound was sutured in two layers with a 5/0 resorbable suture. First the mentalis was sutured with internal interrupted sutures and then the overlying mucosa was closed.



**Figure 7:** 9 months post-operative IOPA showing bone fill.

Presuturing was done between 35 and 36 region. Bone graft was crushed with bone mill and was placed in the bony defect. Suturing was completed. Follow up IOPAs were taken at 1, 3, 6 and 9 months. 9 months postoperative IOPA showed significant bone fill (figure 7).

## DISCUSSION

The Piezosurgery system can use ultrasonic vibration to work only on hard tissues, without any damage to adjacent soft tissue. Piezoelectric surgical devices do not cause soft tissue lacerations or burns during osteotomy. This system makes micrometric bone cuts deep in the oral cavity, resulting in precise and easy-to-control osteotomies, in contrast to rotary burs or reciprocation saws. In 1981, Aro *et al* showed that there are chances of necrosis of cut bone caused by surgical burs, trephines and necrosis<sup>13</sup>. In the same year Horton *et al* published a study on the clinical applications of ultrasound in bone surgery<sup>14</sup>. Dr. Tomaso Vercellotti in 1998 invented Piezosurgery device for harvesting a bone graft. Jonathon Schofield and Amit Patel<sup>12</sup> reported that the surgical control in mobilizing a block graft is easier by piezosurgery than by conventional methods. The force necessary to produce a cut is much less compared to rotational burs, trephines or reciprocating microsaws. These authors also noted that when a bur or trephine is used in bone of an increased density, there is a consequent increase in hand pressure to compensate for the bone density, which results in a decrease in surgical sensitivity. The piezosurgery inserts (tips) vibrate within a width of 60-210µm with an advanced oscillation controlled module. Therefore an increase in temperature is avoided, which ultimately reduces the risk of bone damage as a result of overheating. When bur is used for cutting it wastes a lot of bone and the resultant harvested block is often smaller than first intended. A trephine will make a very fine cut with very little bone wastage. However, it will only allow a circular cortico-cancellous

block to be harvested, which is not ideal. The piezosurgery osteotomy makes a narrow cut with little bone wastage. It allows a block of bone to be cut to match the size of the recipient site. In 1975, Horton *et al*<sup>15</sup> compared alveolar bone healing in surgical defects produced by ultrasound with the defects produced using a chisel or rotary instruments. They found good results with all three techniques. Vercellotti T *et al*<sup>16</sup> published an in vitro study in dogs, comparing bone healing using the Piezosurgery® device, conventional tungsten carbide drills or diamond drills to create 4 mm bone defects around the posterior mandibular teeth. The authors concluded that Piezosurgery® device offered the best results in terms of bone regeneration. In present study, corticocancellous bone graft is harvested from symphyseal region and placed in bone defect. There is evidence to show that only cortical bone grafts are slowly revascularised and that they never completely repair<sup>17</sup>. Conversely, a purely cancellous bone graft is prone to early resorption<sup>12</sup>. So our aim was to harvest corticocancellous bone graft. This device has bone marker. So with the help of this device we can easily harvest cortico-cancellous bone graft. Chiriac *et al*.<sup>18</sup> compared the viability, growth and cell differentiation of bone grafts harvested with a piezoelectric device and a conventional rotary instrument. The authors concluded that neither system interfered with joining of the bone grafts to the recipient bone bed. They obtained satisfactory results with the Piezosurgery® device in harvesting bone grafts, with subsequent correct healing in the recipient bed. Microvibrations and reduced noise minimize patient's psychological stress and fear during surgery under local anesthesia because it makes much less noise and vibrations than conventional rotary instruments. Giulio Preti, Germana Martinasso *et al*<sup>19</sup> reported that Piezoelectric bone surgery appears to be more efficient in the first phases of bone healing; it induced an earlier increase in BMPs (bone morphogenic proteins), controlled the inflammatory process better and stimulated bone remodeling as early as 56 days post-treatment. The downside of the device is the relative slow sawing process. We needed about 30 seconds for one cut of the relatively small bone. This is about 20 seconds longer than the time needed for cutting with the usual saw.

## CONCLUSION

The Piezosurgery® system constitutes an innovation in bone surgery, with handling characteristics, that are different from those of the conventional techniques which makes harvesting of bone graft easier. The piezosurgery unit has added to the armamentarium to achieve the best results for patients with the minimum of trauma. It

removes bone precisely and easily without damaging soft tissues. As a result, even less experienced, though properly trained surgeons can perform this technique of harvesting intraoral autogenous bone graft from symphysis region more effectively with Piezosurgery device.

## REFERENCES

1. Kennedy JE, Ter Haar GR, Cranston D. High intensity focused ultrasound: Surgery of the future? *Br J Radiol*, 76, 590-599, 2003.
2. Maintz G. Animal experiments in the study of the effect of ultrasonic waves on bone regeneration *Strahlentherapie*, 82, 631-638, 1950.
3. Peñarrocha Diago M, Ortega Sánchez B, García Mira B et al. Evaluation of healing criteria for success after periapical surgery. *Med Oral Patol Oral Cir Bucal*, 13, E143-7, 2008.
4. Martí-Bowen E, Peñarrocha-Diago M, García-Mira B. Periapical surgery using the ultrasound technique and silver amalgam retrograde filling. A study of 71 teeth with 100 canals. *Med Oral Patol Oral Cir Bucal*, 10, E67-73, 2005.
5. Vercellotti T. Technological characteristics and clinical indications of piezoelectric bone surgery. *Minerva Stomatol*, 53, 207-214, 2004.
6. Eggers G, Klein J, Blank J, Hassfeld S. Piezosurgery: An ultrasound device for cutting bone and its use and limitations in maxillofacial surgery. *Br J Maxillofac Surg*, 42, 451-453, 2004.
7. Metzger MC, Bormann KH, Schoen R, Gellrich NC, Schmelzeisen R. Inferior alveolar nerve transposition- an in vitro comparison between piezosurgery and conventional bur use. *J Oral Implantol*, 32, 19-25, 2006.
8. Mauro Labanca, Flavio Azzola et al - Piezoelectric surgery: Twenty years of use. *British Journal of Oral and Maxillofacial Surgery*, 46, 265-269, 2008.
9. Schlee M, Steigmann M, Bratu E, Garg AK. Piezosurgery-Basics and possibilities. *Implant Dent*, 15, 334-340, 2006.
10. Stübinger S, Kuttenger J, Filippi A, Sader R, Zeilhofer HF. Intraoral Piezosurgery: Preliminary results of a new technique. *J Oral Maxillofac Surg*, 63, 1283-1287, 2005.
11. Von Arx T, Hafliger J, Chappuis V - Neurosensory disturbances following bone harvesting in symphysis : a prospective clinical study. *Clin Oral Implants Res*, 16, 432-439, 2005.
12. Jonathon Schofield and Amit Patel- Using piezosurgery to harvest a block bone graft from the symphyseal region: a clinical case presentation. *Implant dentistry today*, 1(4), 20-24, 2007.
13. Aro H, Kallioniemi H, Aho AJ et al. Ultrasonic device in bone cutting. A histological and scanning electron microscopical study. *Acta Orthopaedica Scandinavica*, 52, 5-10, 1981.
14. Horton JE, Tarpley TM Jr, Jacoway JR. Clinical applications of ultrasonic instrumentation in the surgery removal of bone. *Oral Surg Oral Med Oral Pathol*, 51, 236-242, 1981.
15. Horton JE, Tarpley TM Jr, Wood LD. The healing of surgical defects in alveolar bone produced with ultrasonic instrumentation, chisel, and rotary bur. *Oral Surg Oral Med Oral Pathol*, 39, 536- 546, 1975.
16. Vercellotti T, Nevins ML, Kim DM, Nevins M, Wada K, Schenk RK, et al. Osseous response following resective therapy with piezosurgery. *Int J Periodontics Restorative Dent*, 25, 543-9, 2005.
17. Burchardt H. Biology of bone transplantation. *Orthop Clin North Am*, 18(2), 187-196, 1987.
18. Chiriac G, Herten M, Schwarz F, Rothamel D, Becker J. Autogenous bone chips: Influence of a new piezoelectric device (Piezosurgery) on chip morphology, cell viability and differentiation. *J Clin Periodontol*, 32, 994-999, 2005.
19. Giulio Preti, Germana Martinasso et al - Cytokines and Growth Factors Involved in the Osseointegration of Oral Titanium Implants Positioned Using Piezoelectric Bone Surgery Versus a Drill Technique: A Pilot Study in Minipigs *Journal of Periodontology*, 78(4), 716-722, April 2007.

Source of Support: None Declared  
Conflict of Interest: None Declared