

A comparative study of functional outcome following philos plating versus percutaneous pinning in proximal humerus fractures

Uidesh Yadav^{1*}, Bharth N², Vaithilingam Ramaiyah Vignesh³, Akhil Chakrawarty⁴

^{1,4}JR, ²Associate Professor, Department of Orthopaedics, AVMC and H, Puducherry, INDIA.

³SR, Department of Orthopaedics, IGGG Hand PGI, Puducherry, INDIA.

Email: yudheesh95@gmail.com

Abstract

Background: Proximal humerus fractures account for approximately 5% of all fractures. Stable minimally displaced fractures can be treated nonoperatively but the management of displaced fractures remain controversial with various modalities of treatment available. **Aim:** This study was aimed at determining the rate of union, complications, operative risks and comparing the clinical functional outcome following ORIF (PHILOS plating) with CRIF (percutaneous K-wire fixation) for 3 and 4-part proximal humerus fracture patients. **Methodology:** study was conducted at AVMC and H from 10-2017 till 10-2019 in orthopaedics department, total 44 patients with 3 and 4-part proximal humerus fracture (ORIF (PHILOS): 21; CRIF (K-wire) :23), Neer's classification of proximal humerus was used to classify fracture, minimum 6 months follow-up, Functional outcome was assessed using Constant-Murley shoulder score. **Results:** Of the 21 patients (ORIF with PHILOS), all fractures united radiologically and clinically and average constant score at final follow-up was 85.29. Of the 23 patients (CRIF with K-wire), average constant score at final follow-up was 79.48. **Conclusion:** Our study demonstrates that locking plate fixation gives good functional outcomes in treatment of proximal humerus fractures. Our results are comparable to various studies conducted by other authors which states that locking plates (PHILOS) provide better functional and radiological outcomes as compared to other fixation methods like percutaneous K-wire fixation, non-locking plates, intramedullary nails, Tension band wiring.

Key Word: proximal humerus fractures.

*Address for Correspondence:

Dr Uidesh Yadav, JR, Department of Orthopaedics, AVMC and H, Puducherry, INDIA.

Email: yudheesh95@gmail.com

Received Date: 03/07/2020 Revised Date: 12/08/2020 Accepted Date: 10/09/2020

DOI: <https://doi.org/10.26611/1031623>

This work is licensed under a [Creative Commons Attribution-NonCommercial 4.0 International License](https://creativecommons.org/licenses/by-nc/4.0/). 

Access this article online	
Quick Response Code:	Website: www.medpulse.in
	Accessed Date: 19 November 2020

INTRODUCTION

Proximal humerus fracture has become one of the most common fracture encountered now a day in orthopaedic clinics. And this recent increase in the incidence of this injury is because of increase of machineries in daily life routine of man. Road traffic accidents have major part in it. Proximal humerus fracture treatment does not have major complications but when affects the working person

it leads to loss of working hours for months and temporary disability. In such cases it becomes important to restore the function of limb. Treatment of this injury is purely depended on the classification and according to types non-operative and operative treatment is decided by the orthopaedic surgeon. As non-union rate is low, non-operative treatment is preferred for the minimal displaced fractures. And in old and osteoporotic bones minimally invasive techniques are used. Treatment for proximal humerus fracture is daily evolving and new implants are being designed by implant companies. Whereas when fracture is severely comminuted and displacement is more preferred treatment is hemiarthroplasty. Minimal amount of malunion which do not hamper the function of limb or cosmetically can be accepted. Whether to choose non-operative treatment or go with surgical procedure can be debatable as there are many studies favouring the both modalities. We conducted a study at our institute and its main purpose was to compare functional outcome of two modalities as treatment of proximal humerus fracture.

How to cite this article: Uidesh Yadav, Bharth N, Vaithilingam Ramaiyah Vignesh, Akhil Chakrawarty. A comparative study of functional outcome following philos plating versus percutaneous pinning in proximal humerus fractures. *MedPulse International Journal of Orthopedics*. November 2020; 16(2): 18-26. <https://www.medpulse.in/Orthopedics/>

Modalities were percutaneous pinning and open reduction and internal fixation with PHILOS. In this study the complications (osteonecrosis, malunion, non-union, infection, neurovascular injury, adhesive capsulitis) rate following procedures were also compared.

AIMS AND OBJECTIVES

1. To study the functional outcome of open reduction internal fixation and closed reduction and internal fixation in proximal humerus fracture.
2. To clinically compare the functional outcomes.
3. To determine the rate of union, complications, operative risks, functional outcome and co-morbidities associated with proximal humerus fractures.
4. To compare the efficacy of plate (PHILOS) and percutaneous pinning (K-WIRE) as fixation devices in the treatment of proximal humerus fractures of humerus.

MATERIALS AND METHODOLOGY

A comparative study of functional outcome following proximal humeral interlocking osteosynthesis plating versus percutaneous pinning in proximal humerus fractures was carried out from September 2017 to September 2019 in orthopaedic department of Aarupadai Veedu Medical College and Hospital Puducherry. Total 44 patients of proximal humerus fractures were treated with ORIF using PHILOS (21 patients) and CRIF with percutaneous pinning (23 patients) during this period.

Inclusion criteria:

- Both sex (male / female)
- Skeletally matured patients
- 3-part or 4-part proximal humerus fracture
- Patients willing for surgery and for minimum 6 months follow-up

Exclusion criteria:

- Skeletally immature patients
- Patient not willing for surgery or follow-up
- Medically unfit patients for surgery
- Pathological fractures
- Bedridden patients
- Patients with 2-part proximal fracture or undisplaced fracture

All patients were admitted from casualty or OPD.

TECHNIQUE 1: ORIF with PHILOS



Figure 1: Instruments used for ORIF with PHILOS

PHILOS plate. Power drill. 3.2mm drill bit. 3.2mm drill guide. 3.2mm tap. 3.2mm screw set. Depth gauge. 3.2mm screw driver. And general surgical instruments i.e. artery forceps, retractors, periosteal elevator, reduction clamp, bone lever.

PROCEDURE

Under GA.

position: supine; folded towel under injured shoulder

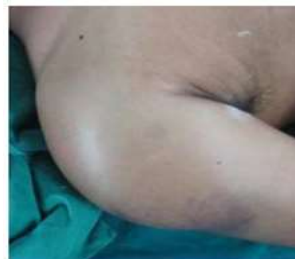

Figure 2: position of patient

From nape of neck, injured side chest, axilla and till finger tips were painted with betadine solution. patient draped with sterile linen approach: Delto-pectoral approach was used for dissection to reach bone and fracture site. Incision was starting just distal to coracoid process and as extended 12-14 cm towards lateral side of the biceps tendon. Skin, subcutaneous tissue (fat, fascia) were divided. Important neurovascular structures were identified and retracted gently. Cephalic vein was given extra care. With the blunt dissection, a space was developed between lateral aspect of proximal humerus and deltoid. In this space Hohman's retractor was placed.

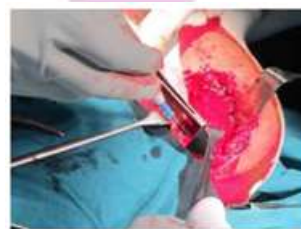

Figure 3: per-op blunt dissection

Deltoid muscle insertion anteriorly on the shaft of humerus was relieved as this improves the exposure and makes space for plate. Under the guidance of fluoroscopy fracture was reduced and was provisionally fixed with K-wire as a temporary fixation. Plate was placed over the fracture laterally after conforming accurate position it was secured to head of humerus and shaft with k-wires.

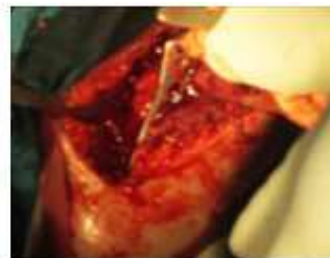


Figure 4: Per-op placing plate

Then screws were placed after checking stability of the fixation wound wash was given with normal saline and metronidazole

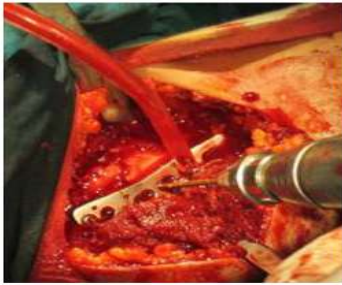


Figure 5: Per-op screw placement

Wound was closed in layers with vicryl and skin staples or ethilon suture.

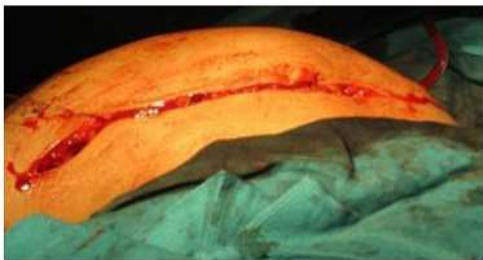

Figure 6: Per-op closure in layers

Sterile dressing was done and patient was shifted to post-operative ward for observation.

POST-OPERATIVE CARE

NPO for 6 to 8 hrs. IVFs were continued as per patient. V antibiotics total 6 doses were given. analgesics as per patient complaints. arm pouch was used for immobilization of operated upper limb. same day of surgery post-op check x-ray was taken. dressing and wound inspection was done on the 2,5,7 post-op day. suture removal was done on POD 12

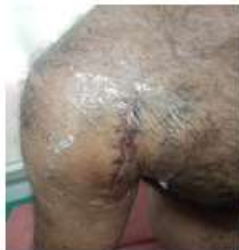

Figure 7: post-op day 12 for suture removal

At discharge patient was advised for immobilisation of operated arm for 2 weeks and arm pouch was given. Tight fist and gentle movement of elbow was advised. Rehabilitation programme was started after 2 weeks of surgery.

REHABILITATION PROGRAMME

Pendulum exercises at operated shoulder were started after 2 wks of surgery. Gentle range of motion exercises at the

operated shoulder were started at the end of 2 weeks. 3 simple and easy exercises were told to the patients which he/she could at his/her residence without any supervision

1. Shoulder rotation: clockwise and anticlockwise
2. Touching the opposite shoulder with the thumb of operated side
3. Assisted lifts: both on front and sides
4. after 6 weeks completion ROM exercises with gravity resistance without any assistance were started.

TECHNIQUE 2: PERCUTANEOUS K-WIRE FIXATION

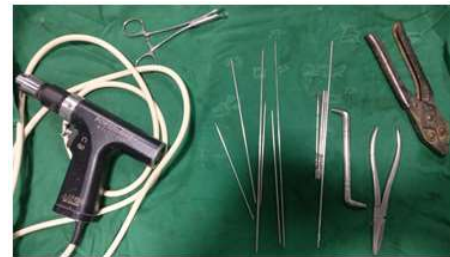

Figure 8: Instruments used in percutaneous k-wire fixation

1.5 -3 mm k-wire. Power Drill. Bone hook. K-wire bender. K-wire cutter. Plier

Procedure

Patient in supine position with folded towel under to be operated shoulder. The humeral shaft and head segment are therefore aligned at the surgical neck by placing the arm into adduction and internal rotation. Apex anterior deformity is corrected with a posterior force and K-wires placed as for two-part surgical neck fractures. The arm is then placed into neutral rotation and abduction. A percutaneously placed bone hook is used to secure the greater tuberosity and to reduce it into the correct position. Fixation is achieved with two K-wires placed from the tuberosity and directed into the medial cortex of the proximal humerus. Access to the head is gained through the split between the greater and lesser tuberosities, almost invariably 5 mm behind the bicipital groove. Once coronal alignment of the head has been corrected, the head is fixed with two pins from the distal lateral humeral cortex into the humeral head. By reducing the humeral head, the greater tuberosity will usually regain its anatomic position, tethered by the bridging periosteum distally and the rotator cuff proximally. The greater tuberosity is then fixed either with K wires. These should be directed into the head proximally and into the shaft distally. The arm is then brought into 70 degrees of abduction and internal rotation to obtain an axillary view of the shoulder to visualize the profile of the anterior proximal humerus. The lesser tuberosity is then controlled with a bone hook and reduced under fluoroscopic guidance into its anatomic position.

The arm is then mobilized under fluoroscopic visualization to confirm adequate stability.

The lateral pins are cut to allow subcutaneous placement.

Postoperative Care:

NPO for 6 to 8 hrs. IVFs were continued as per patient. I. V antibiotics total 6 doses were given. analgesics as per patient complaints. arm pouch was used for immobilization of operated upper limb. same day of surgery post-op check x-ray was taken. at discharge patient was advised for immobilisation of operated arm for 4 weeks and arm pouch was given. tight fist and gentle movement of elbow was advised. rehabilitation programme was started after 4 weeks of surgery. as radiological sign of union was visible and clinically also it was evident k-wire were removed under local anaesthesia

REHABILITATION PROGRAMME

Pendulum exercises at operated shoulder were started after 4 weeks of surgery. Gentle range of motion exercises at the operated shoulder were started at the end of 4 weeks. 3 simple and easy exercises were told to the patients which he/she could at his/her residence without any supervision

- Shoulder rotation: clockwise and anticlockwise
- Touching the opposite shoulder with the thumb of operated side
- Assisted lifts: both on front and sides

After 7 weeks completion ROM exercises with gravity resistance without any assistance were started.

Follow up:

Follow-up schedule for all patients was same despite of technique used for their treatment of proximal humerus fracture. For the first month after surgery patients were called every week and were examined. For the second month, they were called with an interval of 15 days. Once the signs of union were evident the interval between the visits was increased and it became once in a month but patient was on regular physiotherapy. For tenderness, instability, deformity and movements the operated shoulder was examined on each visit. X-rays were taken at each visit for the patients who underwent CRIF with K-wires to know about progressive fracture union and implant position whereas with patients operated with the ORIF with PHILOS radiographs were obtained at 2 weeks apart. According to the stage of fracture union rehabilitation programme was adjusted for the patients. Patients were followed up minimum for 6 months. Constant and Murley score was used for assessing the functional outcome of the patients.

RESULTS AND OBSERVATION

Our study consists of 44 patients of fresh 3 and 4-part fracture of proximal humerus which were treated surgically with open reduction and internal fixation using PHILOS system in 21 patients and closed reduction and

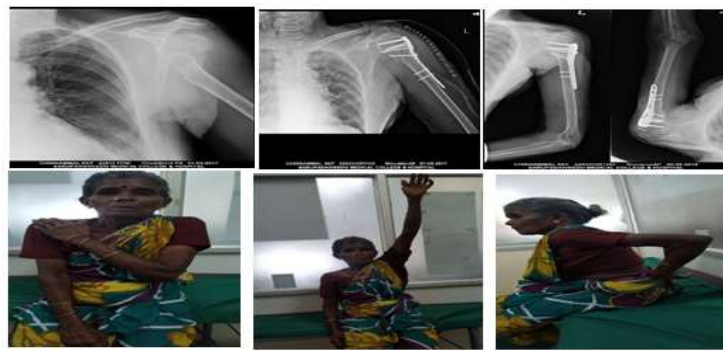internal fixation with k-wire in 23 patients from august 2017 to February 2019. All patients were followed for total 6 months with every week one visit for first month, then every 2 weeks one visit and then one visit in every month. Results were analysed both clinically and radiologically. mode of injury by which patient sustained proximal humerus fracture. In the group of CRIF with k-wire fracture, 11 patients (47.8%) had simple fall and 12 (52.2%) patients had road traffic accident. Whereas in 21 patients who were treated with ORIF with PHILOS system fracture occurred by simple fall in 9(42.9%) patients and 12(57.1%) patients sustained fracture by road traffic accident. age incidence in our study. Age was divided into intervals of 21-40, 41-60 and >60yrs. In group which was treated with k-wire 6 patients belonged to 21-40yrs of age, 14 patients belonged to 41-60yrs of age and 3 patients were more than 60yr old. Whereas in group treated with PHILOS had 4 patients with 21-40yr of age, 13 were with 41-60yr of age and 4 were more than 60yr of age. mean age of patients in our study. Mean age in patients treated with PHILOS was 50.29 where as in patients treated with k-wire was 50.70. proximal humerus fracture treated with CRIF with K-wire majority 65.2% were female and 34.8% were male whereas in patients treated with ORIF, PHILOS system 76.2% were female and 23.8% were male. in 44 patients with proximal humerus fracture, left side was affected in 19 patients from which 11 (47.8%) were treated with CRIF (k-wire) and 8 (38.1%) with ORIF (PHILOS). Whereas right side was affected in 25 patients out of which 12 (52.2%) were treated with CRIF with K-wire and 13 (61.9%) were treated with ORIF (PHILOS). proximal humerus fracture according to Neer's classification. In total 44 patients, 27 patients were diagnosed as 3-part and 17 were 4-part. In 27 patients with 3-part proximal humerus fracture 15 (65.2%) were treated with CRIF (k-wire) and 12 patients treated with ORIF (PHILOS). In 17 patients with 4-part proximal humerus fracture 8(34.8%) patients were treated with CRIF (k-wire) and 9(42.9%) were treated with ORIF (PHILOS). out of 44 patients of proximal humerus fracture, 1 patient had 3rd Metatarsal fracture; 3 had clavicle fracture; 1 had intertrochanter fracture of femur; 6 had ribs fracture; 1 had right shoulder dislocation; 1 had scapula fracture and 31 patients did not have any associated injuries. Fracture was taken as united when there was no tenderness and unprotected full function of limb was possible. In group which was operated with ORIF (PHILOS) mean time of union was 11.10 weeks with S.D of 1.09 (In 10wks union happened in 10 patients; union took place in 12wks in 10 patients; 13wks time was taken only by 1 patient.). whereas for group operated with CRIF(k-wire) mean time of union was 11.74 weeks with S.D of 1.01(in 10wks union took place in 5 patients; 12wks in 13 patients and 13wks in 4 patients

and 1 case in our study which was treated with CRIF (k-wire) went for avascular necrosis). In all 44 patients, functional outcome was measured using constant-murley score. In patients treated with CRIF (k-wire) had excellent result in 7 patients (30.04%) whereas patients treated with ORIF (PHILOS) 10 (47.6%) had excellent results. Good result was found in 7 (30.4%) patients treated with CRIF (k-wire) and 8 patients (38.17) treated with ORIF (PHILOS). Fair result was found in 8 (34.8%) patients treated with CRIF (K-wire) and 3(14.3) patients treated with ORIF (PHILOS).The mean constant-murley score in patients treated with CRIF (k-wire) was 79.48 whereas patients treated with ORIF (PHILOS) had mean constant

murley score of 85.29 Poor result was seen in 1 patient who was treated with CRIF (K-wire) Post-surgical stiffness was most common complication encountered in our study with 17.4% patient being affected in the group who were treated with CRIF (K-wire) and 9.5% patients were affected who were treated with ORIF (PHILOS).Infection was second most common complication faced in our study, 3 (13.0%) patients were affected who were treated with CRIF (k-wire) and 2 (9.5%) patients in ORIF (PHILOS) group. Whereas only 1 case landed in avascular necrosis which was treated with CRIF (k-wire) and 1 patient who was treated with ORIF (PHILOS) developed impingement.

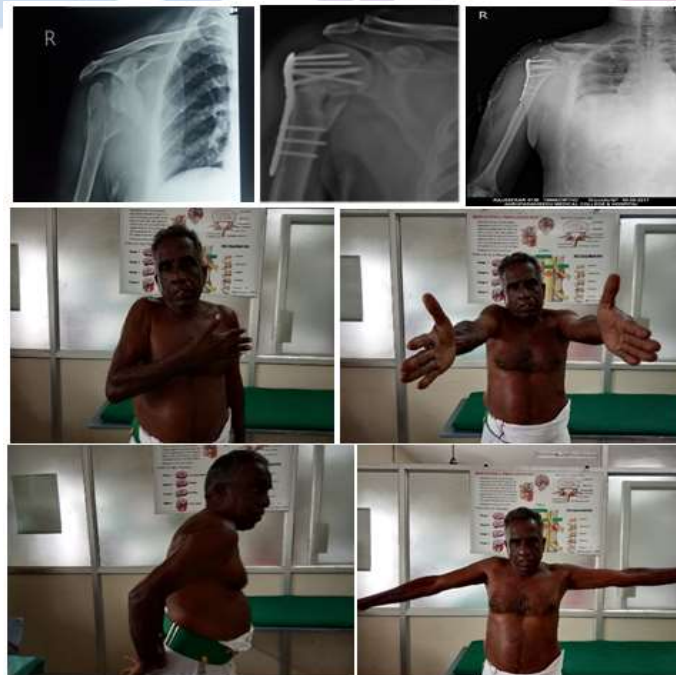
Illustrated cases

Case 1



Preoperative Postoperative 12-month follow-up
Figure 23: range of motion of left shoulder joint post-surgery

Case 2



Preoperative Postoperative 12-month follow-up
Figure 24: Range of motion of left shoulder joint post-surgery

Case 3

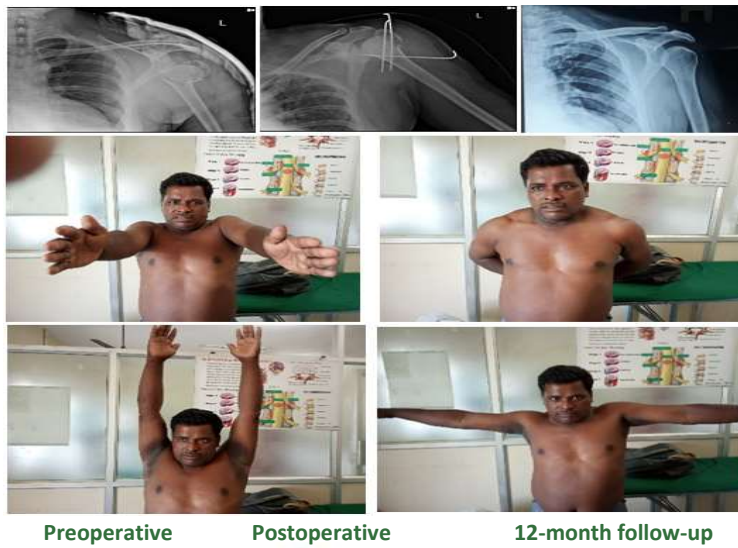

Figure 25: range of motion of left shoulder joint post-surgery

Case 4

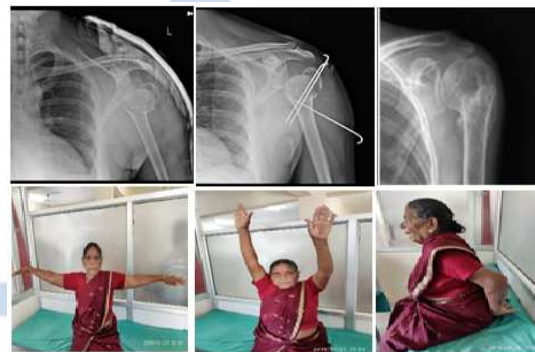

Figure 26: range of motion of left shoulder joint post-surgery

DISCUSSION

Proximal humerus fracture is the second most common fracture seen in upper limb fracture after distal radius fracture and most common fracture seen around shoulder joint.

There have been many options available when comes to treatment of proximal humerus fractures such as:

- non-operative conservative management for undisplaced fractures
- percutaneous screw/pin fixation
- open reduction and internal fixation with plate and screw
- nailing
- replacements
- external fixator

Generally proximal humerus fractures are seen in all age groups; RTA (road traffic accident) or high velocity injury being most common cause in younger patients

whereas trivial falls leading to proximal humerus fracture in elderly or osteoporotic bones. And treating these fractures in osteoporotic bones have become challenging to surgeons due to severely comminution, fracture pattern and cut through by screws. Zyto and colleagues reported mean constant score of 65 points and no complications with conservative treatment compared with surgical approach, resulting in mean value of 60 points and with complications (AVN, infection).⁹ In Clifford's (19980) series of 80 patients whose proximal humerus fracture were treated conservatively, results were excellent or satisfactory in 81%.³ Mangovern, kenner, and Nho found good constant scores with surgery and relatively few complications, with better functional scores for percutaneous fixation.^{10,11,12}

PHILOS has disadvantages of excessive soft tissue dissection and blood loss, risk of injury to neurovascular structures and increased risk of avascular necrosis of humeral head.^{13,14} But good long-term results of proximal humerus fracture

managed by PHILOS plate.^{15,16} Patients who have 3-part or 4-part proximal humerus fracture are more prone for poor clinical results and high failure rates especially when the fixation has been performed with conventional non-locking plates.^{17,18} Locking plates provides better stability than conventional plates that were used in the past.¹⁹⁻²¹ Many authors have demonstrated that they give better functional outcome and also avoid complications.²²⁻²⁷ Hence, the fixed angle plates enable a gain in the torsional stiffness and stability and may therefore promote a superior outcome and less chance of complication like cut-out of the screws and plates, non-union, avascular necrosis and fracture distal to plate.²⁸ Maintenance of medial periosteal hinge and careful surgical dissection prevents damage to the posteromedial vessels at posteromedial neck of humerus, thus decreasing the incidence of AVN in follow-ups.⁴ In a cadaveric study of MIPO, Gardner and colleagues demonstrated preservation of humeral head arterial supply, which included the ascending branch of anterior circumflex vessel and an unnamed posterior branch, when the plate was placed in the “bare spot” on the proximal lateral region of the humerus.² Dolfiet *et al.*²⁹ operated Type II, Type III, and Type IV fractures of proximal humerus using distally threaded dynamic hip screw guide pins, 2 mm K-wires, or 2.5 mm distally threaded Schantz pins. In their study, all patients with Neer’s Type IV fractures did not respond to fixation and three had avascular necrosis (AVN), irrespective of the type of pin used. They concluded that stable fixation with early motion and subsequently good results can be obtained using percutaneous fixation in patients with Type II and Type III fractures; however, terminally threaded pins must be used and smooth K-wires must be avoided. Percutaneous fixation cannot be recommended in patients with Type IV fractures. The present study was done at Aarupadai Veedu Medical College and Hospital, Puducherry during period from September 2017 to September 2019. In the study, a total of 44 cases of fresh proximal humerus fracture were treated by using open reduction and internal fixation with PHILOS and percutaneous pinning with simple K-wire. These both the groups were evaluated preoperatively; details were collected in a preformed proforma; operated and were followed for at least 6 months on OPD basis. The data collected for both the groups was analysed and compared with each other, the result is compared with previous studies. In our study, female predominance was seen with total 31 patients and 13 male patients. Similarly in vijay, *et al.*⁷ study female predominance was seen with 28 female patients and 20 male. Whereas in study conducted by jaura, *et al.*² he reported 36 male patients and 24 female patients. In our study, 24 patients sustained

fracture following road traffic accident and 20 patients had a simple self-fall. Whereas vijay, *et al.*⁴ reported in his study simple fall on ground as most common cause for fracture in 28 patients and road traffic accident in 16 patients. Mean age in our study is 50 years, this depicts the role of osteoporosis in proximal humerus fracture. Vijay, *et al.*⁴ reported similar in their study. Kralinger, *et al.*⁸ also reported the similar results. In our study right humerus was fractured more, 25 patients and 19 patients had left humerus involvement. Vijay, *et al.*⁴ reported the similar results in their study. Fracture union has never been a problem in proximal humeral fracture management as had been mentioned in many studies^{6,9,10,11} due to cancellous nature of bone unless anatomical neck or articular part of humerus is involved, compromising bone of its blood supply. In our study, fractures in 43 patients united successfully. There were no cases of delayed union or nonunion in our study but 1 case went for avascular necrosis which was treated with K-wire. The average time for union (in weeks) was found to be 11 (ranging 10–13 weeks) and was unaffected by the modality of treatment used. Vijay, *et al.*⁴ reported the similar results in his study with average time for union of 10.34 weeks. In our study 23.80% of patients treated with PHILOS developed some post-operative complication and 34.78% of patients treated with K-wire. Jaura, *et al.*¹ and vijay, *et al.*⁴ reported the similar results in their study. In our study mean constant-murley score in patients treated with PHILOS was 85.29, while for patients treated with K-wire was 79.48. jaura GS, *et al.*¹, vijay, *et al.*⁴, hiren, *et al.*⁷, kralinger, *et al.*⁸ all reported the similar results in their respective studies. Early rehabilitation was paramount for obtaining good range of movements and prevention of stiffness.⁴ The recent evolution of locking plate technology for proximal humerus fractures seems to have revolutionized the management of these fractures. However, there have been very limited prospective studies investigating the results of locking plates for open reduction and internal fixation of proximal humeral fractures. Most of these studies have reported good functional outcomes and recommended the use of locking plates for proximal humerus fractures especially in elderly patients with poor bone quality.⁵ We, thus believe, that a locking plate device for proximal humerus fractures gives a satisfactory outcome in most of the patients including those with old the age and poor bone density.

CONCLUSION

- Proximal humerus fractures are usually treated conservatively but there are specific indications for which operative treatment is needed like three and four-part displaced proximal humerus fractures.

- Among the internal fixation methods intramedullary fixation do not control rotation so they require longer period of immobilization till union.
- In this study primary, open reduction and internal fixation with PHILOS plate system of fresh proximal humerus fractures provides a more rigid fixation and does not require immobilization for longer periods (2weeks) whereas in patients treated with K-wire required immobilization at least for four weeks.
- The PHILOS plate can be a very rigid construct if locking screws are used both proximally and distally. This can produce a stress concentration at the surgical neck of the humerus.
- This can be reduced by using standard screws in the humeral shaft, which reduces the rigidity of the construct. In osteoporotic bone, bicortical self-tapping locking screws should be used so as to increase the working length of the screw and avoid a potential problem at the interface between the screw thread and the bone. Increasing the distance between the plate and the bone can also reduce the stability of the construct.
- In our study, all fractures united except one patient (4%) who had avascular necrosis which was treated with K-wire. Excellent to good results obtained in 85.71% of the patient treated with PHILOS plate system and the mean Constant score was 85.29. whereas patients treated with CRIF (K-wire) excellent to good results were obtained in 60.86% patients and mean constant score was 79.48.

Our result demonstrated that the PHILOS system provides better and stable fracture fixation for early mobilization especially in Osteoporotic bone when compared with K-wire as treatment option for proximal humerus fracture type III and IV. Early results with PHILOS plate system were promising, and if plate is placed at optimal position and proper physiotherapy is given results can be better.

References

1. GS Jaura, MBBS, J Sikdar, MS Orth, S Singh, MBBS Long Term Results of PHILOS Plating and Percutaneous K-Wire Fixation in Proximal Humerus Fractures in The Elderly *Malaysian Orthopaedic Journal* 2014 Vol 8 No 1
2. Dr.GantaVaraprasad, Dr.Venkatanaresh Kumar D Three Part Proximal Humerus Fracture Fixation with K-wires Vs Minimally Invasive Locking Plate International Journal of Science and Research (IJSR) ISSN (Online): 2319-7064 Index Copernicus Value (2013): 6.14 | Impact Factor (2013): 4.438
3. Pekka Paavolainen, Jan-Magnus Björkenheim, PärSlätisand Perth Paukku (1983) Operative Treatment of Severe Proximal Humeral Fractures, *Acta Orthopaedica Scandinavica*, 54:3, 374-379, DOI: 10.3109/17453678308996587
4. Vijay A, Kumar M, Bhaskar SK, Rao BS, Gandhi M. Comparison of open reduction internal fixation with proximal humerus interlocking system and close reduction and pinning with K-wire in proximal humeral fracture. *J OrthopTraumatolRehabil*2017;9:99-105.
5. Dr. NateshKolusu and Dr. Shravan Kumar Peddamadyam AnjaneyuluFunctional outcome of displaced proximal humerus fractures treated conservatively versus open reduction internal fixation with locking compression plate, *International Journal of Orthopaedics Sciences* 2018; 4(1): 504-509
6. Francesco Muncibi, Diana Chicon Paez, Fabrizio Matassi, Christian Carulli, Lorenzo Nistri, Massimo InnocentiLong term results of percutaneous fixation of proximal humerus fractures *Indian Journal of Orthopaedics* | November 2012 | Vol. 46 | Issue 6
7. Hiren PK, Ankit KB, Modi VJ. Comparison of the results and outcomesof the different modalities (closed v/s open) of the treatment of theproximal humerus fractures. *Indian J Appl Res* 2014;4:323-5.
8. Kralinger F, Irenberger A, Lechner C, Wambacher M, Golser K,Sperner G. Comparison of open versus percutaneous treatment forhumeral head fracture. *Unfallchirurg*2006;109:406-10.
9. Zyto K, Ahrengart L, Sperbert A, TorknvistH.Treatment of displaced proximal humeral fractures in elderly patients. *J Bone Joint Surg [Br]* 1997; 79: 512-7.
10. Magovern B, Ramsay ML. Percutaneous fixation of proximal humerus fractures. *OrthopClin North Am* 2008; 39: 405-16.
11. Nho SJ, Brophy RH, Baker JU, Cornell CN, Mac Gillivray JD. Management of proximal humerus fractures based on current literature. *J Bone Joint Surg [Am]* 2007; 89: 44-58.
12. Kenner JD, Parsons BO, Flatow EL, Rogers K, Williams GR, Galatz M. Outcomes after percutaneous reduction and fixation of proximal humerus fractures. *J Shoulder Elbow Surg*2007; 16: 330-8.
13. Siegel J, Dines D. Proximal humerus malunions. *OrthopClin North Am* 2000; 31: 35-49.
14. Wijnman AJ, Roolker W, Pall TW, Raaymakers EL, Marti RK. Open reduction and internal fixation of three- and four-part fractures of the proximal part of the humerus. *J Bone Joint Surg*1970; 52: 1077-89.
15. Hirschmann MT, Fallegger B, Amsler F, Regazzoni P, Gross T. Clinical longer term results after internal fixation of proximal humerus fractures with alocking compression plate(PHILOS). *J Orthop Trauma* 2011; 25: 286-93.
16. Olerud P, Ahrangart L, Ponzer S, Saving J, Tidemark J. Internal fixation versus non operativetreatmentt of displaced 3 part proximal humerus fractures in elderly patients: A randomised controlled trial. *J Shoulder Elbow Surg*2011; 20: 747-55.
17. Kristiansen B, Christensen SW. Plate fixation of proximal humeral fractures. *Acta Orthop Scand*. 1986;57(4):320-23.
18. Paavolainen P, Björkenheim JM, Slati P, Paukku P. Operative treatment of severe proximal humeral fractures. *Acta Orthop Scand*. 1983;54(3):374-79.
19. Weinstein DM, Bratton DR, Ciccone WJ II, Elias JJ. Locking plates improve torsional resistance in the stabilization of three-part proximal humeral fractures. *J Shoulder Elbow Surg*. 2006;15(2):239-43.
20. Walsh S, Reindl R, Harvey E, Berry G, Beckman L, Steffen T. Biomechanical [40] comparison of a unique locking plate versus a standard plate for internal fixation

- of proximal humerus fractures in a cadaveric model. *ClinBiomech.* 2006;21(10):1027-31.
21. Siffri PC, Peindl RD, Coley ER, Norton J, Connor PM, Kellam JF. Biomechanical [41] analysis of blade plate versus locking plate fixation for a proximal humerus fracture: comparison using cadaveric and synthetic humeri. *J Orthop Trauma.* 2006;20(8):547-54.
 22. Helmy N, Hintermann B. New trends in the treatment of proximal humerus [1]fractures. *ClinOrthop.* 2006;442:100-08.
 23. Björkenheim JM, Pajarinen J, Savolainen V. Internal fixation of proximal humeral [9] fractures with a locking compression plate: a retrospective evaluation of 72 patients followed for a minimum of 1 year. *Acta Orthop Scand.* 2004;75(6):741-45.
 24. Fankhauser F, Boldin C, Schippinger G, Haunschmid C, Szyszkowitz R. A new [11] locking plate for unstable fractures of the proximal humerus. *ClinOrthopRelat Res.* 2005;430:176-81.
 25. Kettler M, Biberthaler P, Braunstein V, Zeiler C, Kroetz M, Mutschler W. Treatment of proximal humeral fractures with the PHILOS angular stable plate. Presentation of 225 cases of dislocated fractures. *Unfallchirurg.* 2006;109(12):1032-40.
 26. Sudkamp N, Bayer J, Hepp P, *et al.*. Open reduction and internal fixation of proximal humeral fractures with use of the locking proximal humerus plate. Results of a prospective, multicenter, observational study. *J Bone Joint Surg Am.* 2009;91(6):1320-28.
 27. Koukakis A, Apostolou CD, Taneja T, Korres DS, Amini A. Fixation of proximal humerus fractures using the PHILOS plate: early experience. *ClinOrthopRelat Res.* 2006;442:115-20.
 28. Lill H, Hepp P, Korner J, Kassi JP, Verheyden AP, Josten C, *et al.*. Proximal humeral fractures: how stiff should an implant be? A comparative mechanical study with new implants in human specimens. *Arch Orthop Trauma Surg.* 2003;123:74- 81.
 29. Dolfi H Jr., Saunders DT, Johnson MP, Roy S, Thomas D. Percutaneous fixation of proximal humeral fractures. *ClinOrthop*2000;375:97-104.

Source of Support: None Declared
Conflict of Interest: None Declared

Policy for Articles with Open Access:

Authors who publish with MedPulse International Journal of Orthopedics, (Print ISSN: 2579-0889, Online) (ISSN: 2636-4638) agree to the following terms: Authors retain copyright and grant the journal right of first publication with the work simultaneously licensed under a Creative Commons Attribution License that allows others to share the work with an acknowledgement of the work's authorship and initial publication in this journal. Authors are permitted and encouraged to post links to their work online (e.g., in institutional repositories or on their website) prior to and during the submission process, as it can lead to productive exchanges, as well as earlier and greater citation of published work.