

# Orbital cysticercosis presenting as proptosis

Vikas Chennamaneni

Department of Radiology and Imaging, Prathima Institute of Medical Sciences, Nagunoor, Karimnagar District, Andhra Pradesh, INDIA.

Email: [vikas\\_ch\\_rao@yahoo.com](mailto:vikas_ch_rao@yahoo.com)

## Abstract

Orbital cysticercosis is a less common presentation of cysticercal infestation. Diagnosis is primarily by CT and MRI investigations. High resolution ultrasound is rarely used in the diagnosis. Patients can be managed conservatively with antihelminths and steroids. We present the case of a 10 years old girl presenting with proptosis of left eye and was diagnosed as extraocular orbital cysticercosis involving the inferior rectus muscle on high-resolution ultrasound and managed conservatively with antihelminths.

**Keywords:** Orbital cysticercosis, inferior rectus muscle, high resolution ultrasound.

## \*Address for Correspondence:

Dr. Vikas Chennamaneni, Department of Radiology and Imaging, Prathima Institute of Medical Sciences, Nagunoor, Karimnagar District, Andhra Pradesh, INDIA.

Email: [vikas\\_ch\\_rao@yahoo.com](mailto:vikas_ch_rao@yahoo.com)

Received Date: 28/01/2015 Revised Date: 21/12/2015 Accepted Date: 18/10/2016

## Access this article online

Quick Response Code:	Website: <a href="http://www.medpulse.in">www.medpulse.in</a>
	DOI: ---

## INTRODUCTION

Cysticercosis in humans is infection by the larval form of the pork tapeworm *Taenia solium*. The location of cysts in order of frequency is the central nervous system, subcutaneous tissue, striated muscle, vitreous humour of the eye and, rarely, other tissues. Orbital cysticercosis is a less common presentation and high resolution ultrasound can help in clinching the diagnosis and avoid unnecessary interventions. We describe a rare ultrasound diagnosis of isolated orbital cysticercosis involving the inferior rectus muscle of left eye, diagnosed with ultrasound and managed conservatively.

## CASE HISTORY

A 10 years old girl reported to the Department of Radiology and Imaging, Karimnagar, India with proptosis of left eye since one month. There was gradual increase in proptosis. There was association with pigs in her colony.

## Examination

On examination, there was restriction of eye movements. Systemic examination of the patient was normal and there was no other abnormality.

## Investigations

Ophthalmoscopy was normal. Haematological findings were normal. The patient was sent to the Department of Radiology and Imaging for an ultrasound examination of the left eye. On ultrasound there was a well-defined cystic lesion measuring 15 x 8mm containing a small echogenic nidus (Figure 1) noted in the region of inferior rectus muscle. Because of this characteristic appearance on ultrasound examination, a diagnosis of orbital cysticercosis involving the inferior rectus muscle was made.

## Treatment

The patient was managed conservatively and prescribed albendazole 400mg tablets twice daily for 15 days along with tapered dose of steroids. After 15 days of conservative treatment, the lesion showed resolution and the patient appeared well.

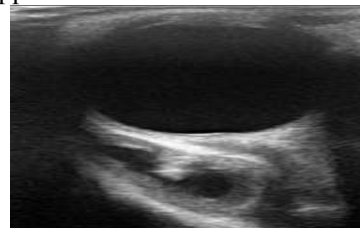


Figure 1:

## DISCUSSION

Cysticercosis is an infection with the larval stage of *Taenia solium*. It is seen as cysts in various human

tissues, more commonly in the brain, skeletal muscle and subcutaneous tissues. It is endemic in most parts of Asia and is transmitted by the fecal-oral route<sup>1</sup>. Humans normally act as definitive hosts. Humans can occasionally be intermediate hosts. It is transmitted to humans by ingestion of eggs from contaminated water or food, such as vegetables<sup>2</sup>. The eggs hatch in the small intestine releasing oncospheres that penetrate the bowel mucosa and enter the bloodstream to reach various tissues, where they develop to form a cysticercus cellulosae, which is the encysted larval form of *Taenia solium*. These can remain viable in this stage for as long as 10 years in humans. Living larvae evade immune recognition and do not elicit inflammation. When the larva dies, it induces a vigorous granulomatous inflammatory response that may produce symptoms, depending on the anatomic location<sup>3</sup>. Cysticercosis is the most common parasitic disease of the central nervous system worldwide, but isolated orbital cysticercosis has been reported much less frequently. Extraocular cysticercosis represents most common type of ocular cysticercosis. In the ocular form, favoured sites are vitreous and subretinal space. Symptoms may include periorbital pain, ptosis, restricted ocular movements and light flashes. Diagnosis of ocular cysticercosis is usually made by direct ophthalmic demonstration of larval form. USG, CT and MRI are other modalities used

in the diagnosis. However MRI is the best modality for diagnosing intraocular cysticercosis. Medical treatment is known to cause severe intraocular complications which may lead to blindness. Hence it is of paramount importance to diagnose the location of orbital cysticercosis. Extraocular form of orbital cysticercosis can be medically managed<sup>4</sup>. In conclusion, high-resolution ultrasound, being non-invasive and non-ionizing, plays an important adjuvant role in establishing the diagnosis in patients with orbital cysticercosis<sup>5</sup>.

## REFERENCES

1. Despommier DD. Tapeworm infection: the long and the short of it. *N Engl J Med* 1992; 327:727-728.
2. Abdelwahab IF, Klein MJ, Hermann G, Abdul-Quader M. Solitary cysticercosis of the biceps brachii in a vegetarian: a rare and unusual pseudotumor. *Skeletal Radiol* 2003; 32:424-428.
3. Botero D, Tanowitz HB, Weiss LM, Wittner M. Taeniasis and cysticercosis. *Infect Dis Clin North Am* 1993; 7:683-697.
4. Nijjar I, Singh JP, Arora V, Abrol R, Sandhu PS, Chopra R, Roopa. MRI in intraocular cysticercosis - A case report. *Indian J Radiol Imaging* 2005; 15: 309-10.
5. Dubey RB, Tara NP, Sisodiya KN. Computerised tomographic evaluation of orbital lesions: Pictorial essay. *Indian J Radiol Imaging* 2003; 13: 261-70.

Source of Support: None Declared  
Conflict of Interest: None Declared