

Ruptured intracranial sellar-suprasellar dermoid - a case report

Jagdish Aher^{1*}, A. P. Oak², B. H. Kombade³, M. M. Kadam⁴, U. M. Dhumal⁵

^{1,2,3,4,5}Department of Radiology, Government Medical College, Latur, Maharashtra, INDIA.

Email: drjagdishaher@gmail.com

Abstract

Intracranial dermoids comprise less than 1% of all intracranial lesions. These are slow growing benign congenital ectodermal inclusion cysts containing varying amounts of ectodermal derivatives. They usually found in midline in contrast to epidermoids. Teratomas, although similar in some respects, are a separate entity. Intracranial dermoid cysts show variable presentation usually cause symptoms because of mass effect and due to rupture with spillage of its contents into subarachnoid space and/or ventricles is a potentially serious complication that can lead to aseptic meningitis, seizures, cerebral ischaemia, hydrocephalus and rarely olfactory ischaemia. Occasionally they are incidentally detected.^{1,3,4} Summary: Rupture of intracranial dermoid is very uncommon occurrence with significant mortality. We present a case of ruptured sellar-suprasellar dermoid with subarachnoid and intraventricular dissemination of its contents causing hydrocephalus.

Keywords: suprasellar, dermoid cyst, magnetic resonance imaging.

*Address for Correspondence:

Dr. Jagdish Aher, Department of Radiology, Government Medical College, Latur, Maharashtra, INDIA

Email: drjagdishaher@gmail.com

Received Date: 14/02/2015 Revised Date: 10/12/2015 Accepted Date: 18/10/2016

Access this article online

Quick Response Code:	Website: www.medpulse.in
	DOI: ---

disturbances, tingling and numbness in upper and lower extremities bilaterally. There were signs of meningeal irritation seen on physical examination. There were no focal neurological deficits seen. There was h/o headache since 3 months which was relieved by analgesics. CSF study showed elevated leucocytes. CT scan showed large round to oval well defined hypodense lesion of size 50x45mm in sellar- suprasellar region with partially calcified margin and causing mild mass effect on cerebellar peduncles. Attenuation of lesion was -40 to 15 HU. There are low attenuation foci of fat seen along cerebral sulci of bilateral cerebral hemispheres. There was moderate dilatation of bilateral lateral and 3rd ventricles with fat fluid levels noted within Fig 1.

CASE REPORT

A 50 year old male patient presented with altered consciousness, intense excruciating headache, visual

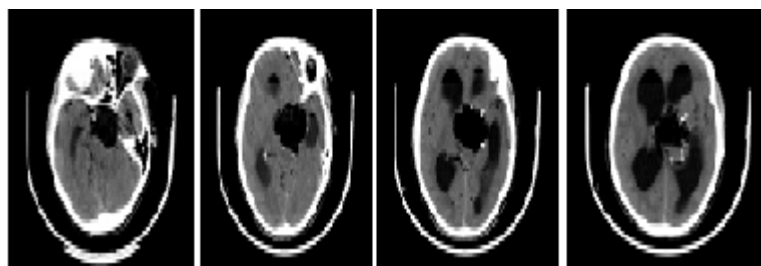


Figure 1

MRI brain plain study showed large heterogenous mass lesion in sellar-suprasellar region appearing heterogeneously hyperintense on T2WI/FLAIR images and hypointense on T1WI with peripheral hyperintense areas (Fig2 A and B).It is causing severe effacement of 3rd ventricle and foramen of monro. There is moderate

dilatation of ventricular system with fat fluid level seen in frontal horns of bilateral lateral ventricles. There are multiple hyperintense spots seen on T1WI in basal cisterns, sulcal spaces and sylvian fissure s/o subarachnoid dissemination of fat.

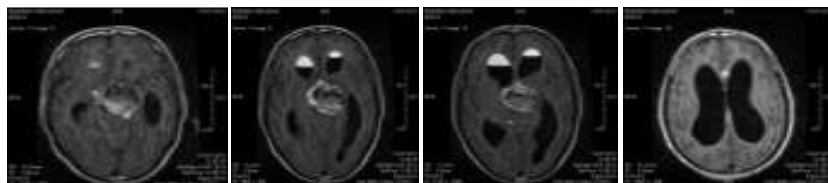


Figure 2A

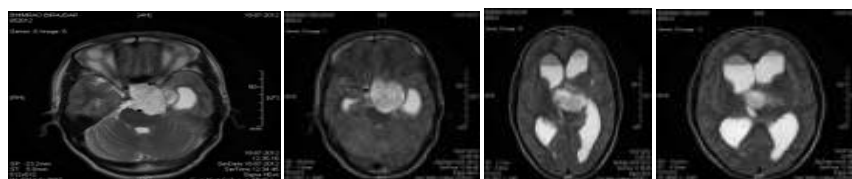


Figure 2B

A diagnosis of ruptured sellar-suprasellar dermoid with subarachnoid and intraventricular dissemination of its contents causing hydrocephalus was made.

DISCUSSION

Intracranial dermoid cystic tumors are rare, benign, slow-growing masses. They are mostly found below the tentorium, usually in midline, either in cavity of 4th ventricle or in vermis. There is often associated dermal sinus. Supratentorial dermoid cysts are less common. Suprasellar and pineal dermoids are rare sites. Cranial abnormalities such as bone defects, dermal sinus are not associated with supratentorial dermoids⁶ Supratentorial dermoids often present in the second or third decades of life, while posterior fossa dermoids typically present in the first decade of life as a consequence of mass effect exerted on the fourth ventricle with resulting hydrocephalus⁶. Dermoid are thick walled cysts lined by squamous keratinized epithelium and contains thick viscous fluid comprising of lipid metabolites cholesterol and whorls of hair; sebaceous glands may be seen³. Intracranial dermoids show variable presentation; typically symptoms are due to mass effect created on adjacent intracranial structures and spillage of contents due to rupture. Dermoid cystic tumor rupture usually occurs spontaneously; however, cases of rupture secondary to closed head trauma or iatrogenic surgical complications have been reported⁵. If rupture occurs, aseptic chemical meningitis may ensue with profound irritative effects from the disseminated cholesterol debris. Chemical meningitis is a relatively rare development. Chemical meningitis may elicit transient cerebral ischemia secondary to vasospasm with complicating

infarction that may result in the death of the patient. Symptom onset typically does not occur at the time of rupture, since the irritative effects of the spilled contents require time to develop, but may be delayed from 3 months to 6.5 years after rupture .Suprasellar dermoids reveal themselves early with visual disturbances or headache due to hydrocephalus^{1,4,5}. Occasionally intracranial dermoid tumors are asymptomatic and found incidentally. Imaging features of intracranial dermoid tumors on brain CT scans are virtually pathognomonic. These lesions will have internal density characteristics consistent with fat (negative HU), although density values greater than fat may be seen depending on the internal cyst contents. The dermoid wall is typically seen and can calcify. Occasionally the wall will at least partially enhance following the administration of CT-iodinated contrast material. On MRI scans, dermoids will be hyperintense on T1-weighted imaging and heterogenous on T2-weighted imaging. If the internal fat content is relatively low, the lesion will reveal CSF-like signal intensity⁵. In such cases, fluid attenuation inversion recovery (FLAIR) is useful, in that the fat will appear hyperintense on a background of suppressed fluid signal (dark). On MRI, fat constituents create a so-called “chemical shift” artifact due to misregistration of the signal in the frequency-encoded direction. This can be particularly useful in diagnosing these lesions preoperatively. When a dermoid tumor ruptures, fat droplets—appearing hypodense on CT or hyperintense on T1WI in MRI—may be seen scattered and floating within the nondependent portions of the ventricular system and/or subarachnoid space. This is considered a classic imaging feature of these lesions. In the setting of

complicating chemical meningitis, intense pial and ventricular ependymal enhancement may be detected after the administration of MRI gadolinium contrast^{1,2,8}. Although there is no literature about use of MRS in diagnosing dermoids but it may show fat contents of dermoid. Differential diagnosis includes epidermoid cyst arachnoid cyst and cystic craniopharyngiomas. Cystic craniopharyngiomas and arachnoid cyst can be differentiated from dermoids based on signal characteristics and demonstration of fat in dermoids and using FLAIR sequences. The location of epidermoid is more variable than that of dermoid cyst and shows greater deviation from midline. Following complete or near total excision of the tumors, the recurrence is rare, contrary to epidermoids that are known to recur¹. Rare reports describe the development of squamous cell carcinoma in retained remnants of a dermoid cystic tumor wall⁷. Patients' age, clinical history, location of the lesion, presence of calcifications and low density on CT and demonstration of fat content on MRI favour the diagnosis of dermoid

REFERENCES

1. Venkatesh SK, Phadke RV, Trivedi P, Bannerji D. Asymptomatic spontaneous rupture of suprasellar dermoid cyst: a case report. *Neurol India*. 2002; 50(4): 480–483.
2. Smirniotopoulos JG, Chiechi MV. Teratomas, dermoids, and epidermoids of the head and neck. *Radiographic* 1995; 15(6):1437–1455.
3. Miller Jb: *Northfield's surgery of the central nervous system*, 2nd edition, Oxford, Blackwell.1987; 240-244.
4. Patkar D, Krishnan A, Patankar T, Prasad S, Shah J, Limdi J. Ruptured intracranial dermoids: magnetic resonance imaging. *J Postgrad Med*. 1999; 45(2):49–52.
5. Das CJ, Tahir M, Debnath J, Pangtey GS. Neurological picture. Ruptured intracranial dermoid. *J Neurol Neurosurg Psychiatry*. 2007; 78(6):624–625.
6. Lunardi P, Missori P: Supratentorial dermoid cysts. *J Neurosurg* 1991; 75: 262-266.
7. Tsugu H, Fukushima T, Hayashi S, Iwaasa M, Matsuda T. Squamous cell carcinoma arising in an intracranial dermoid cyst—case report. *Neurol Med Chir (Tokyo)* 2001; 41(4):213–216.
8. Osborn AG, Preece MT. Intracranial cysts: radiologic-pathologic correlation and imaging approach. *Radiology*. 2006; 239(3):650–664.

Source of Support: None Declared
Conflict of Interest: None Declared