

High resolution ultrasound and magnetic resonance imaging correlation of rotator cuff tears

R Archana¹, Prashanth Mamidipalli^{2*}

¹Associate Professor, ²Post Graduate, Department of Radiodiagnosis, Osmania Medical College, Hyderabad, Telangana, INDIA.

Email: adiiti1234@yahoo.com

Abstract

Background: Rotator cuff disease is one of the most common causes of shoulder pain. In addition to history and physical examination, several radiological techniques have been used to detect tears of the rotator cuff. Each has limitations and no clear consensus on the optimum diagnostic study has emerged. The radiological diagnosis of rotator cuff tears has traditionally been performed with arthrography and more recently with non-invasive techniques like ultrasonography and MRI. **Aims:** Evaluation of role of MRI in rotator cuff injuries, evaluation of role of high resolution ultrasound in rotator cuff injuries. Correlation of clinical and high resolution ultrasound findings with MRI findings. **Materials and Methods:** Proportional analysis of 30 patients with clinically suspected rotator cuff injuries were subjected to undergo USG and MRI after thorough history taking and clinical examination. USG was carried out on IU22 Philips machine using a high frequency transducer of 5-17 MHz. The rotator cuff tendons, muscles, ACJ, joint cavity and bursae were examined in various positions. Dynamic examination of shoulder were also carried out for impingement. MRI was performed on 1.5 Tesla MRI scanner, using a dedicated surface coil for shoulder. **Results:** Majority of the rotator cuff tears were seen in patients above 50 yrs of age (40%) with males affected more than females (M:F ratio - 5:1), dominant arm (83.3%) affected more than the non dominant arm with 75% of the cases with history of trauma showing rotator cuff tears depicting the fact that increasing age, male gender, dominant arm and history of trauma are predisposing factors for rotator cuff tears. Pain was the most common clinical complaint (43.3%) followed by inability to do overhead abduction (23.3%) in our study in patients with rotator cuff tears. Partial tears (66.67%) were more common than the full thickness tears (23.33%). Among the partial tears most common were articular surface tears in 85% followed by bursal tears in 10% and intrasubstance tears in 5%. 75% of the patients with peribicipital tendon fluid had rotator cuff tears showing significant association between peribicipital tendon fluid and rotator cuff tears. **Conclusion:** MRI is more sensitive and has highest diagnostic accuracy in detecting rotator cuff tears as compared to USG and clinical diagnosis. **Key Words:** Peribicipital tendon, Rotator cuff tears, shoulder joint.

* Address for Correspondence:

Dr. Prashanth Mamidipalli, Post Graduate, Department of Radiodiagnosis, Osmania Medical College, Hyderabad, Telangana, INDIA.

Email: adiiti1234@yahoo.com

Received Date: 12/08/2018 Revised Date: 03/09/2018 Accepted Date: 21/10/2018

DOI: <https://doi.org/10.26611/1013814>

Access this article online

Quick Response Code:



Website:

www.medpulse.in

Accessed Date:
24 October 2018

INTRODUCTION

The shoulder joint is an incongruous ball and socket joint without any fixed axis of rotation, which has a wide range

of motion in multiple planes; hence stability is compromised for mobility. To compensate for the unstable bony anatomy the shoulder is protected anteriorly, posteriorly and superiorly by a capsule and the tendons that form the rotator cuff. The tendon is subject to "wear and tear" during the day to day activities. Spectrum of etiologies that can give rise to shoulder pain are acute trauma to a gamut of degenerative disorders associated with impingement syndrome. Repetitive active and passive forces render these tendons susceptible to degeneration leading to swelling of the tendon and a minor degree of subluxation. The space between the humeral head and the acromion is sufficiently restricted that mild swelling of the interposed tendon with or without minor superior subluxation of the humeral head leads to impingement syndrome and rotator cuff tears.

Patients presenting for imaging fall broadly into one of the following categories: Specific pain and restricted movements on abducting the arm and symptoms of instability. Several radiological techniques have been used to detect tears of the rotator cuff. Each has limitations and no clear consensus on the optimum diagnostic study has emerged¹. The radiological diagnosis of rotator cuff tears has traditionally been performed with arthrography and more recently with ultrasonography and MRI². Rotator cuff disease is one of the most common causes of shoulder pain. In addition to history and physical examination, evaluation of a patient with shoulder pain often involves assessment of the rotator cuff with a diagnostic test such as high resolution ultrasonography or MRI³. High resolution ultrasound is non invasive, less expensive and non-ionizing modality with good sensitivity in detecting both rotator cuff and non rotator cuff disorder.⁴ MRI has become the "gold standard" for detecting both subtle and obvious internal derangement and assessing overall joint structure.⁴ MRI can provide information about rotator cuff tears such as tear dimensions, tear depth or thickness and tear shape, involvement of adjacent structures (eg, rotator interval, long head of biceps brachii tendon etc) and muscle atrophy, all of which have implications for rotator cuff treatment and prognosis. Information about coracoacromial arch and impingement as it relates to rotator cuff tears can also be obtained with MRI⁷. Arthrography is quite accurate in detecting complete tears but it is an invasive procedure with some associated risk and discomfort, in addition it is insensitive to partial tears involving superficial surface or substance of the cuff. The diagnosis of partial tears, however, is important because many orthopedic surgeons will operate to relieve impingement of supraspinatus tendon before it progresses to full thickness tear. The relative ease with which they are seen on MRI suggests that MRI may have a role in their diagnosis². Although non-invasive, MRI is considerably more expensive than ultrasonography and will probably not replace it as a screening procedure for those trained in its use. For those cases in which the sonogram yields indeterminate results or in those institutions in which no one is trained to do sonography of the shoulder, MRI may be a useful screening test². The major disadvantages of MRI are the long examination time, expense and that the study may be unsuccessful in very large or claustrophobic patients.⁸ Arthrography appears to be more accurate in diagnosing rotator cuff injuries than either MRI or ultrasound but that benefit must be set against the invasiveness and potential discomfort to patients. Ultrasonography is as accurate as MRI for both full thickness and partial thickness tears, these results combined with low cost for ultrasound

suggests that ultrasound may be the most cost effective imaging method of screening for rotator cuff injuries provided that the examiner is trained in this operator dependent technique. For practitioners without ultrasound expertise, MRI can be used. Arthrography can be performed in those cases in which ultrasound and MRI are not definitive⁹. In our study of thirty patients with shoulder joint pain, with a clinical suspicion of rotator cuff injuries were subjected to USG and MRI of the shoulder joint.

MATERIALS AND METHODS

It is a Proportion study in 30 patients referred to the department of Radio diagnosis, J.J.M. Medical College, Davangere with clinically suspected rotator cuff injuries were subjected to undergo USG and MRI after thorough history taking and clinical examination. September 2012 to November 2014

Inclusion Criteria: All patients with clinical suspicious of rotator cuff injuries, all age groups irrespective of sex

Exclusion Criteria: Patient having history of claustrophobia, Patient having history of metallic implants insertion, cardiac pacemakers and metallic foreign body insitu. After clinical evaluation, once a patient satisfied the inclusion and exclusion criteria for this study, he or she would undergo USG and MRI examination after giving consent.

Ultrasound examination of the shoulder: Was carried out on IU22 Philips machine using a high frequency transducer of 5-17 MHz. The rotator cuff tendons, muscles, ACJ, joint cavity and bursae were examined in various positions. Dynamic examination of shoulder were also carried out for impingement. Comparison with opposite shoulder was also done.

MRI examination of the shoulder: was performed on 1.5 Tesla MRI scanner (Achieva, Philips), using a dedicated surface coil for shoulder. Patient was placed in supine position with external rotation of affected shoulder wherever possible. The following sequences were used: Short T1 inversion recovery (STIR) in the axial plane, a slice thickness of 3mm, a FOV of 150mm and TR/TE – 7913/170. Proton density images in the oblique coronal plane, a slice thickness of 3mm, a FOV of 140mm and TR/TE – 4500/30. T2 weighted images in the oblique coronal plane, a slice thickness of 3mm, a FOV of 140mm and TR/TE – 4375/100. T2 weighted images with fat suppression (SPAIR) in the oblique coronal plane, a slice thickness of 3mm, a FOV of 140mm and TR/TE – 4000/50. Proton density images in the oblique sagittal plane, a slice thickness of 3mm, a FOV of 140mm and TR/TE – 4500/30. Short T1 inversion recovery (STIR) in the oblique sagittal plane, a slice thickness of 3mm, a FOV of 140mm and TR/TE – 3443/60. Data was entered

into Microsoft excel sheet and was analyzed using EPI Info 7 version software. Qualitative data was represented in the form of Frequency and Proportions. Chi-square was the test of significance to find the association between qualitative data. Validity of the diagnostic test was measured by Sensitivity, Specificity, Positive predictive value, Negative predictive value and Diagnostic accuracy. Kappa statistics was computed to find the Degree of agreement between two diagnostic tests. p value < 0.05 was considered as statistically significant.

RESULTS

The age of the patients with rotator cuff pathologies studied ranged from 23 to 76 years, with a mean of 46.6 +/- 2.08. The patients involved in the study were divided into 3 age groups viz. <40 years, 41-50 years, >50 years. Of the 30 patients studied, 5(16.7%) were females and 25 (83.3%) were males. The mean age among females was 54 + /-1.98 and the mean age among males was 45.12+/- 2.2. In our study majority of the patients were right handed i.e. 86.6% and 13.4 % were left handed. All the 4 left handers (100%) had Rotator cuff injuries on left side and 80.7% of right handers had injuries on right side.

Table 1: The various abnormalities in the rotator cuff tendons and the age range of occurrence in our study group.

Status of rotator cuff tendon	Age range in years			Total
	<40	41-50	>50	
Normal	4	1	0	5
Tendinosis	3	1	1	5
Partial tear	1	5	6	12
Full thickness tear	1	2	5	8
Total	9	9	12	30

In patients with age more than 50 yrs, 11 (36.7%) patients show tears as compared to less than 50 years, where 9 (30%) patients show tear in the rotator cuff tendons. In patients more than 50yrs of age, 1(3%) showed tendinosis and in less than 50 years 4(13.3%) showed tendinosis. Thus in this study tears appear to be common in older age groups than in younger patients, with tears being more common than tendinosis in older age groups.

Table 2: Clinical presentation among the patients with Rotator cuff injuries

Clinical Data	Frequency	Percent
Pain	13	43.3
Stiffness	4	13.3
Inability to do overhead abduction	7	23.3
Pain and Stiffness	3	10.0
Weakness	1	3.3
Pain And Weakness	2	6.7
Total	30	100.0

Majority of the patients with rotator cuff injuries presented with pain (43.3%), followed by Inability to do overhead abduction in 23.3%, Stiffness in 13.3%, pain and stiffness in 10%, pain and weakness in 6.7% and weakness in 3.3%.

Table 3: History of Trauma in subjects

		Frequency	Percent
H/o trauma	Absent	22	73.3
	Present	8	26.7
	Total	30	100.0
Range of Movements	Decreased	23	76.7
	Normal	7	23.3
	Total	30	100.0

In our study 26.7% of patients had history of trauma. In our study 76.6% of patients had decreased range of movements.

Table 4: Results of Clinical tests in various Rotator cuff injuries

		Frequency	Percent
Clinical tests	Positive for Supraspinatus	20	66.7
	Positive for Infraspinatus	2	6.7
	Positive for Subscapularis	2	6.7
	SS and SC positive	2	6.7
	SS and IS positive	1	3.3
	SS, IS and SC positive	1	3.3
	IS and SC positive	2	6.7
	Total	30	100.0

In our study 66.7% patients showed positive clinical test for Supraspinatus muscle, 6.7% for Infraspinatus injuries and Subscapularis respectively. 20% of patients showed positive clinical test for more than one muscle.

Table 9: USG and MRI findings in Tendon injuries

		USG	IP	SUB	TM	BT	
Tendons	No tear		17	29	26	30	30
	Articular surface partial tear		5	0	2	0	0
	Bursal surface partial tear		2	0	0	0	0
	Full thickness tear		3	1	2	0	0
	Intrasubstance tear		1	0	0	0	0
	Tendinosis		2	0	0	0	0
	Total		30	30	30	30	30
MRI	No tear		8	28	24	30	30
	Articular surface partial tear		10	1	4	0	0
	Bursal surface partial tear		2	0	0	0	0
	Full thickness tear		3	1	2	0	0
	Intrasubstance tear		1	0	0	0	0
	Tendinosis		6	0	0	0	0
	Total		30	30	30	30	30

In USG it was observed that 11 patients had tendon tear of supraspinatus muscle, 1 patient had Infraspinatus tear, 4 patients had Subscapular tear and there was no tear in Teres minor and Biceps tendon. 2 patients had tendinosis of supraspinatus muscle. In MRI it was observed that 16 patients had tendon lesions of supraspinatus muscle, 2 patients had Infraspinatus tear, 6 patients had Subscapular tear and there was no tear in Teres minor and Biceps tendon. 6 patients had tendinosis of supraspinatus muscle.

Table 4: Validity of USG findings with MRI findings in Tendon Injuries

	Sensitivity	Specificity	Positive Predictive value	Negative Predictive value	Diagnostic Accuracy	Kappa Degree of agreement
SS	59.09%	100%	100%	47.06%	70%	0.43
IP	50%	100%	100%	96.55%	96.67%	0.65
SUB	66.67%	100%	100%	92.31%	93.33%	0.76
TM	-	100%	-	100%	100%	-
BT	-	100%	-	100%	100%	-

USG findings in comparison to MRI findings showed that Sensitivity of USG was low in detecting the Tendon injuries at all the sites. Highest sensitivity was observed for Sub scapular tendon injuries. Specificity was 100% at all the sites. Diagnostic accuracy was low in Supraspinatus tears and Highest for Teres minor and Biceps tendon injuries. The agreement between USG and MRI findings was measured by Kappa and highest agreement was observed for subscapular tears.

Table 5: Calcification diagnosed by USG and MRI

Calcification diagnosed by USG		Frequency	Percent
Supraspinatus	Absent	29	96.7
	Present	1	3.3
Infraspinatus	Absent	30	100
Subscapularis	Absent	30	100
Teres minor	Absent	30	100
Biceps tendon	Absent	30	100
Calcification diagnosed by MRI			
Supraspinatus	Absent	29	96.7
	Present	1	3.3
Infraspinatus	Absent	30	100
Subscapularis	Absent	30	100
Teres minor	Absent	30	100
Biceps tendon	Absent	30	100

In our study only one patient had calcification in supraspinatus tendon. In the study one patient was diagnosed to have calcification in Supraspinatus tendon.

Table 6: Validity of USG findings with MRI findings in detecting Calcification

	Sensitivity	Specificity	Positive Predictive value	Negative Predictive value	Diagnostic Accuracy	Kappa Degree of agreement
SS	100%	100%	100%	100%	100%	1
IP	-	100%	-	100%	100%	-
SUB	-	100%	-	100%	100%	-
TM	-	100%	-	100%	100%	-
BT	-	100%	-	100%	100%	-

USG had similar Sensitivity, specificity, positive predictive value, Negative predictive value and Diagnostic accuracy as MRI in identifying calcifications in Rotator cuff injuries.

Table 7: Association between USG findings and MRI findings in tendon fluid and bursal fluid

		PTF in MRI		Total	χ^2 , df, p value
		Absent	Present		
PTF in USG	Absent	14	1	15	26.25, 1, 0.0001**
	Present	0	15	15	
Total		14	16	30	
Subacromial-subdeltoid bursal fluid (SA-SD) in USG	Absent	15	1	16	26.25, 1, 0.0001**
	Present	0	14	14	
Total		15	15	30	
Subcoracoid bursal fluid (S-C) in USG	Absent	20	2	22	21.81, 1, 0.0001**
	Present	0	8	8	
Total		15	20	10	30

MRI showed 16 patients positive for PTF out of 30 whereas USG detected 15 out of 30 cases and did not detect PTF in one case. There was significant association between USG and MRI findings. i. e. MRI was better in detecting PTF than USG. MRI showed 15 positive for SA-SD bursal fluid out of 30 whereas USG detected 14 cases and did not detect SA-SD in one case. There was significant association between USG and MRI findings. I.e. MRI was better in detecting SA-SD bursal fluid than USG. Similarly MRI showed 10 positive for SC bursal fluid out of 30 whereas USG detected 8 cases and did not SC in two cases. There was significant association between USG and MRI findings. I.e. MRI was better in detecting SC bursal fluid than USG.

Table 8: Association between USG findings and MRI findings in detecting Joint Effusion

			Absent	Present	Total	χ^2 , df, p value
			Joint Effusion in USG	Absent	14	3
	Present	0	13	13		
Total			14	16	30	
CJH in USG	Absent		21	0	21	30.0, 1, 0.0001**
	Present		0	9	9	
Total			14	21	9	30

MRI showed 16 positive for joint effusion out of 30 whereas USG detected in 13 cases and did not detect joint effusion in three cases. There was significant association between USG and MRI findings. i.e. MRI was better in detecting joint effusion than USG. MRI showed 9 positive for ACJH out of 30, USG also detected all the 9 cases of ACJH. There was significant association between USG and MRI findings. I.e. USG was equivalent to MRI in detecting ACJH.

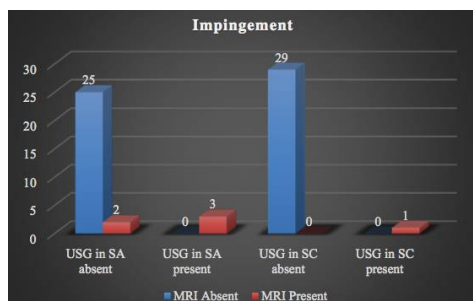


Figure 1: Association between USG findings and MRI findings in detecting Impingement lesions

MRI showed 5 positive for SA impingement out of 30 whereas USG detected 3 cases and did not detect SA impingement in two cases. There was significant association between USG and MRI findings. I.e. MRI was better in detecting SA impingement than USG. Similarly MRI showed 1 positive for SC impingement out of 30, USG also detected 1 case of SC impingement. There was significant association between USG and MRI findings. I.e. USG was equivalent to MRI in detecting SC impingement.

Table 9: Validity of USG findings with MRI findings in detecting PTF, Bursal Fluid, Joint Effusion, ACJH and Impingement

		Specificity	PPV	NPV	Diagnostic Accuracy	Kappa Degree of agreement
Bursal	PTF	93.75%	100%	93.33%	96.67%	0.93
	SA-SD	93.33%	100%	96.67%	100%	0.93
	SC	80%	100%	90.91%	93.33%	0.84
	Joint Effusion	81.25%	100%	82.35%	90%	0.81
	ACJH	100%	100%	100%	100%	1
Impingement	SA	60%	100%	92.59%	93.33%	0.71
	SC	100%	100%	100%	100%	1

In our study it was observed that USG had 100% specificity and Negative predictive value in detecting PTF, SA-SD bursal fluid, SC bursal fluid, Joint effusion, ACJH and Impingement in SA and SC. USG had highest sensitivity for ACJH and SC impingement diagnosis. Least sensitivity was observed for SC Bursal Fluid detection. Diagnostic accuracy was 100% for SA-SD Bursal Fluid, ACJH and SC impingement. Kappa statistics showed that PTF and SA-SD Bursal fluid has highest degree of agreement between USG and MRI.

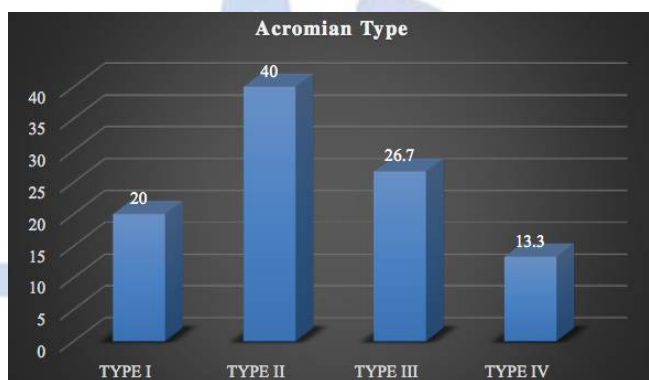


Figure 2: ACROMIAN TYPE

Majority i.e. 40% had Type II Acromian, 26.7% had Type III acromian, 20% had Type 1 acromian and 13.3% had Type IV acromian.

Table 10: MRI Findings of Labral tear and Bone changes

		Percent
Labral Tear	Absent	24 80
	Present	6 20
	Total	30 100
Bone Changes	Normal	17 56.7
	Subchondral cysts	5 16.7
	Erosions/osteophytes	3 10.0
	Edema/contusion	5 16.7

In our study only 20% of patients had associated Labral tear. In our study 13 cases had bone changes of which 16.7% were Subchondral cysts, 10% were erosions/osteophytes and 16.7% were edema/contusion.

Table 11: Comparison of MRI Diagnosis with USG and Clinical diagnosis

	Sensitivity	Specificity	Positive Predictive value	Negative Predictive value	Diagnostic Accuracy	Kappa Degree of agreement
USG vs MRI	66.67%	100%	100%	42.86%	73.33%	0.44
Clinical diagnosis VS MRI	100%	0%	80%	-	80%	0

In our study it was observed that USG had 66.67%, Sensitivity, 100% Specificity, 100% PPV, 42.86% NPV and 73.33% Diagnostic accuracy in diagnosing Rotator cuff injuries. Kappa Agreement between USG and MRI was 0.44 i.e. fair agreement.

Table 12: Comparison of Final Diagnosis with MRI, USG and Clinical diagnosis

	Sensitivity	Specificity	Positive Predictive value	Negative Predictive value	Diagnostic Accuracy	Kappa Degree of agreement
MRI Vs Final diagnosis	92%	80%	95.83%	66.67%	90%	0.66
USG Vs Final diagnosis	64%	100%	100%	35.71%	70%	0.37
Clinical diagnosis Vs Final diagnosis	100%	0	83.33%	-	83.33%	

Final diagnosis was made by arthroscopy/surgery. When MRI, USG and Clinical diagnosis was compared with Final diagnosis it was observed that Diagnostic accuracy was highest for MRI and lowest diagnostic accuracy was seen in USG. Degree of agreement was highest for MRI i.e. 0.66 (Good agreement) and lowest for Clinical diagnosis (0). Full thickness Supraspinatus tendon tear with retraction of tendon.

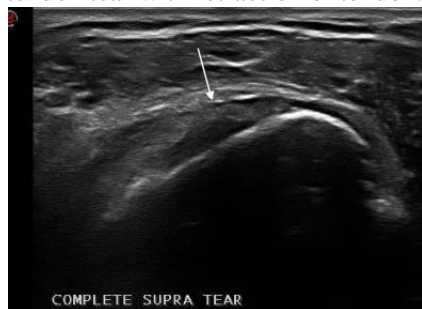

Figure 3: Cases in study

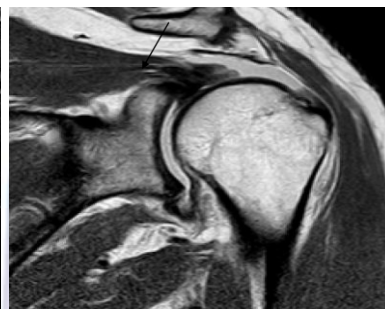


Figure 4

USG and T2w CORONAL MRI images: show discontinuity of supraspinatus tendon with retraction from its insertion site (arrow).

DISCUSSION

Various techniques are used for evaluating patients with rotator cuff tears including clinical examination, X-ray, Arthrography, USG, CT scan and MRI. The gold standard is arthrography but has the disadvantage of being invasive. MRI is sensitive and specific but is expensive and cannot be used as a first line of investigation. However, USG is a non-invasive, relatively inexpensive modality that can be used as a first line of investigation. The soft tissue structures supporting the shoulder are arranged in multiple planes, hence the direct multiplanar imaging capability of MRI is superior to the single plane capability of computed tomography. The rotator cuff is well visualized in MRI and the individual central tendons of the four rotator cuff muscles can be separately identified.² Thus allowing precise localization and quantification of rotator cuff abnormalities. MRI can demonstrate the rotator cuff excellently including the subacromial portion, which is hidden from view on ultrasonography.

Age wise distribution of rotator cuff diseases: In our study the age of the patients with rotator cuff disorders ranged from 23 to 76 years with the mean of 46.6 +/- 2.08. Majority of Rotator cuff injuries were observed in

patients above 50 yrs of age (40%). Various literatures have pointed out that the incidence of rotator cuff tendon degeneration and injury increases with the age. Rotator cuff diseases is multi factorial both extrinsic and intrinsic factors have been implicated. Intrinsic factors like poor vascularity, alteration in the material composition and properties with aging have been studied.³ Ozaki *et al.* and Uthoff believe that the pathogenesis of rotator cuff disorders is an intrinsic process^{3,4} and the risk of rotator cuff disorder increases with aging. Microvascular studies have shown diminished vascularity in the cuff tissue with increased age which appears consistent with the pattern of degeneration observed in age related degenerative tendinopathies.⁵ In a study conducted by Needell *et al*⁶ in 100 asymptomatic shoulders, a higher incidence of tendinosis was found among younger population against more tears in the older age group in the fifth and sixth decade of life. In our study tears appeared to be more common in the age group more than 50 years (36.7%) compared with age group less than 50 years of age (30%). Tendinosis appeared to be more common in the age group less than 50 years (13.3%) compared with age group more than 50 years of age (3%). Our study results are consistent with those of Needell *et al.* The extrinsic

factors like impingement secondary to spurs, osteophytosis, type II and III acromion also increases with age.

Gender distribution of rotator cuff disease: David W.S *et al*,⁷ showed female predominance in case of tendinosis and male predominance among patients with tears. In our study rotator cuff diseases was seen in 25 male patients (83.3%) and 5 female patients (16.7%), thus showing male preponderance among the study population correlating with study of David W.S *et al*.

Association between Dominant side and affected side: Yamamoto *et al*⁸ in their study done on 1366 shoulders concluded that risk factors for rotator cuff tears include increasing age, history of trauma and dominant hand. Urwin M, Symmons D, Allison T, Brammah T, Busby H, Roxby M *et al* (1998) predicted the burden of shoulder disorders in the community. They concluded that rotator cuff tears tend to prevail in the dominant arm.⁹ In our study majority were right handed subjects i.e 86.6% and 13.4 % were left handed subjects. All the 4 left handers (100%) had Rotator cuff injuries on left side and 80.7% of right handers had injuries on right side showing statistically significant association between dominant hand and affected side correlating with study of Yamamoto *et al*⁸ and Urwin M *et al*⁹.

Clinical presentation among the subjects with Rotator cuff injuries: Pain is the most frequently associated complaint with rotator cuff pathology. It is usually located over the anterior, superior, and lateral aspects of the shoulder⁸⁴. Pain usually is minimal at rest in a neutral and supported position of the arm. The pain is typically exacerbated with overhead raising or abduction of arm as in combing hair, especially when lifting against resistance.¹⁰ Weakness may be a manifestation of either pain inhibition or muscular fatigue. True weakness often presents as an inability to raise the arm above the shoulder level. Stiffness may be secondary to pain or weakness of the rotator cuff. Our study showed pain as the most common presenting complaint (43.3%) of rotator cuff disorders, which is consistent with the literature. Many studies have showed disorders of the rotator cuff are the most common causes of a painful shoulder.

History of Trauma: In our study 8 out of 30 patients (26.7%) had history of trauma. 6 out of 8 patients (75%) with history of trauma had rotator cuff tear making it a predisposing factor for rotator cuff tears consistent with literature.⁸

Range of Movements in patients with Rotator cuff Injuries: Decreased range of motion is usually secondary to pain because of rotator cuff tear or weakness of the rotator cuff.⁹ In our study 23 out of 30 patients (76.6%) had decreased range of movements. Out of 23 patients

with decreased range of motion 15 (65.21%) had rotator cuff tear depicting the fact that decreased range of motion is a manifestation of rotator cuff tear which is consistent with the literature.⁵

USG findings in Tendon injuries: In our study most commonly involved tendon was supraspinatus (43.3%), followed by subscapularis (13.3%), infraspinatus (3.3%) with teres minor and biceps tendon least commonly affected (0%). This is consistent with the study conducted by Jerosch *et al*. It was a study conducted on the dissected specimen of shoulder joints of 122 patients; it was found that isolated supraspinatus involvement occurred in 78% cases⁸⁷. It was also noted no tear occurred without the involvement of supraspinatus tendon. DePalma *et al* examined 96 cadaver shoulder and showed similar finding of supraspinatus as the commonly affected tendon and the incidence and degree of tear increased with age.¹¹

MRI findings in Tendon injuries: In our study most commonly involved tendon was supraspinatus (73.3%), followed by subscapularis (20%), infraspinatus (6.67%) with teres minor and biceps tendon least commonly affected (0%). This is consistent with literature.⁸

Correlation of USG findings with MRI findings in Tendon Injuries: USG findings in comparison to MRI findings showed that Sensitivity of USG was low in detecting the Tendon injuries of supraspinatus (59.09%), infraspinatus (50%) and subscapularis muscle (66.67%). Highest sensitivity was observed for Sub scapular tendon injuries (66.67%). Specificity was 100% at all the sites. Diagnostic accuracy was low in Supraspinatus tears(70%) and Highest for Teres minor and Biceps tendon injuries(100%). The agreement between USG and MRI findings was measured by Kappa and highest agreement was observed for subscapular tears (0.76). This is consistent with study done by Martin Hervas. C and his associates who examined all painful shoulders during 1998 by subjecting them to USG and MRI, have stated that the diagnosis of rotator cuff tears was highly specific on both imaging techniques (100% for USG) but was not as sensitive using USG (67.9%).¹²

Correlation of USG with MRI in detection of calcification of rotator cuff tendon: In our study 1 out of 30 patients (3.33%) had calcification of supraspinatus tendon which was detected by both USG and MRI indicating that USG and MRI are equivalent to each other for detecting calcification of rotator cuff tendons.

Correlation of USG with MRI in detection of Peribicipital tendon fluid (PTF): In our study MRI showed 16 positive for PTF out of 30 patients (53.33%) whereas USG detected 15 cases (50%) and did not detect PTF in one case. There was significant association between USG and MRI findings (p value< 0.0001). i.e. MRI was better in detecting PTF than USG. In our study,

peribicipital tendon fluid was found in 16 patients (53.33%). Of these, tear seen in 12(75%), tendinosis was seen in 2(12.5%) and normal tendon seen in 2(12.5%). This was consistent with study done by Doughlas *et al* in 111 patients with shoulder pain who underwent both MR and surgery, found 73 patients with peribicipital tendon fluid. They concluded peribicipital tendon fluid had a statistically significant association with tears of the supraspinatus and subscapularis components of the rotator cuff.¹³

Correlation of USG with MRI in detection of Bursal fluid / Joint effusion: In our study MRI showed 15(50%), positive for SA-SD bursal fluid out of 30 patients whereas USG detected 14 cases (46.67%) and did not detect SA-SD in one case. There was significant association between USG and MRI findings (p value<0.0001). I.e. MRI was better in detecting SA-SD bursal fluid than USG. Similarly MRI showed 10 positive for S-C bursal fluid out of 30 patients (33.33%) whereas USG detected 8 cases (26.67%) and did not S-C in two cases. There was significant association between USG and MRI findings (p value<0.0001). I.e. MRI was better in detecting S-C bursal fluid than USG. In our study MRI showed 16 positive for joint effusion out of 30 patients (53.33%) whereas USG detected in 13 cases (43.33%) and did not detect joint effusion in three cases. There was significant association between USG and MRI findings (p value<0.0001). i.e. MRI was better in detecting joint effusion than USG. In a study by Hollister *et al* done on 97 patients with surgery proven rotator cuff tear 52% had fluid in the joint, bursa or both. It was concluded in this study that fluid in the bursa (subacromial / subdeltoid) / joint effusion had strong association with rotator cuff tears. The specificity and PPV for rotator cuff tears increases when both bursal and joint fluid were present, and careful evaluation of cuff tendons is a warranted to rule out tears in presence of joint effusion or bursal effusion.¹⁴ In our study joint effusion was found in 16 (53.33%) and bursal fluid noted in 20(66.67%).Of the 16 patients with effusion 13 (81.25%) had tears and 1 (6.25%) had tendinosis and 2 (12.5%) had normal tendon. Of the 20 patients with bursal fluid, 17 (85%) showed tear in the cuff tendon and 3 (15%) showed tendinosis in the cuff tendon. Thus presence of joint effusion or bursal effusion is a marker of abnormal cuff tendon especially tears.

Correlation of USG with MRI in detection of Acromio-clavicular joint hypertrophy (ACJH): In our study MRI showed 9(30%), positive for ACJH out of 30 patients. USG also detected all the 9 cases of ACJH. There was significant association between USG and MRI findings (p value<0.0001). I.e. USG was equivalent to MRI in detecting ACJH. Out of 9 patients with ACJH 7

had tear (77.77%), 1 had tendinosis (11.11%) and 1 had normal tendon (11.11%).Thus abnormal tendon was common in patients with AC joint hypertrophy and tear being more frequent in these patients. This was consistent with a study by Needel *et al* in 100 patients in which acromioclavicular joint changes increased with age. More than 80% patients with partial tear and all the patients with full thickness tear showed acromioclavicular joint arthrosis.⁶

Correlation of USG with MRI in detection of impingement: In our study MRI showed 5(16.67%) positive for SA impingement out of 30 patients whereas USG detected 3 cases (10%) and did not detect SA impingement in two cases. There was significant association between USG and MRI findings (p value<0.0001).. I.e. MRI was better in detecting SA impingement than USG. Similarly MRI showed 1(3.33%) positive for SC impingement out of 30, USG also detected 1 case of SC impingement. There was significant association between USG and MRI findings(p value<0.0001). I.e. USG was equivalent to MRI in detecting SC impingement. In our study sensitivity of dynamic USG for detecting impingement was 66.67% as compared to MRI (100%). This was consistent with the study done by John W *et al* to determine the accuracy of ultrasound for the preoperative evaluation of impingement syndrome in which dynamic USG correctly diagnosed 25 out of 37 cases (sensitivity 67.56%). They concluded that dynamic USG can help confirm but not exclude a clinical diagnosis of impingement.¹⁵

Acromian type and rotator cuff disease: Acromion are classified as type I to IV, flat, curved inferior surface, hooked and convex near the distal end, respectively according to Bigliani and colleagues.¹⁶ Type II and III are the most common types and are usually associated with shoulder impingement⁸⁴. Bigliani *et al* in a study in 140 cadavers showed significant increase in full thickness tear with type II acromion. Morrisson and Bigilani in another study found 80% correlation between type II and type III acromion with rotator cuff disease. Ellman in other studied found association of rotator cuff tears with type II and IIIacromions.¹⁷ In our study done in 30 patients with rotator cuff pathologies, most common was type II in 12 (40%) followed by type III in 8 (22%) then type I in 6 (20%) and least common type IV in 4 (13.3%). In this study it was found 66.67% of patients (20 out of 30) had either type II or III acromion. Of these patients 14 (70%) had tears (partial and complete), 3(15%) had tendinosis and 3 (15%) had normal supraspinatus tendon. Thus in this study rotator cuff pathologies were common with type II /III acromion which is consistent with literature.^{16,17}

Labrum and rotator cuff tears: An overlap of symptoms exists among patients with a glenoid labral lesion and those with a rotator cuff disorder or glenohumeral instability. A labral tear can result as a result of trauma like in patients who engage in over head throwing athletic sport activities, or secondary to degenerative changes in the labrum leading on to tear. Rotator cuff tears and long head of the biceps tendinopathy may accompany a superior labral tear. Both chronic overuse tears of the posterosuperior labrum and articular-side partial tears of the supraspinatus and infraspinatus tendons may result from internal impingement in the overhead position. In a study conducted by Glenn *et al* on 41 patients with arthroscopy proven labral tear, it was found 68% patients had both labral and rotator cuff tears.¹⁸ In our study out of the 30 patients, 6 (20%) patients showed glenoid labrum tear. This smaller number may be because of the limitation of magnetic resonance imaging without arthrogram in detecting labral tears.

Adjacent bone changes: Humeral head or greater tuberosity cysts have been associated with shoulder impingement. This is a very common finding on MR exam. These cysts are often posteriorly located, at the greater tuberosity, or at its junction with humeral head near the capsular insertion. Cysts may also occur more superiorly or anteriorly. A recent study done by Huang *et al*¹⁹ in 108 shoulders⁹⁶ compared these bone changes of the humerus as identified on plain radiographs to the presence of rotator cuff pathology on MRI. In this study Identifying cyst like lesions in the greater tuberosity or humeral head was not significantly associated with rotator cuff disease. In our study 13 out of 30 patients (43.33%) showed changes in the adjacent bones like edema, contusion, geodes or subchondral cysts and erosion depending upon the mechanism causing rotator cuff disease or as changes secondary to the rotator cuff disease itself.

Other findings: In our study associated findings included axillary lymph node (14.3%), greater tuberosity avulsion fracture (14.3%), hill sach lesion (14.3%), hill sach lesion with lesser tuberosity fracture (14.3%), humeral head fracture with muscle edema (14.3%) and multiple exostosis arising from humeral head,neck and shaft (14.3%).

Rotator cuff tears: Partial tears of tendon can be intrasubstance i.e. without involvement of the surface or with involvement of surface only on one side i.e. either on the bursal or the articular surface of the tendon. Among our study of 30 patients totally 20 patients had partial tear (66.67%) - 13(65%) in the supraspinatus tendon, 5 (25%) in the subscapularis tendon and 2(10%) in the infraspinatus tendon. The articular surface of the

cuff is hypovascular compared to the bursal surface, resulting in a higher incidence of partial-thickness rotator cuff tears on the articular surface of the cuff 84.97. Articular surface tears are found more common than the bursal surface tears⁹⁸. Jacobson *et al* in a study conducted in 50 patients with surgical correlation found among the partial tears, articular surface tears occurred in 70%. In our study 20 patients had partial tear of the rotator cuff tendons, of these most common were articular surface tears in 85% followed by bursal tears in 10% and intrasubstance tears in 5%, which is consistent with literature. Full thickness tears are ones in which the tear traverses through the whole thickness, extending from one surface to the other. Presence of fluid in the subacromial –subdeltoid bursa is a common finding. Complete or full thickness tear is more frequent in supraspinatus⁸⁵. In our study full thickness tear was seen in 7 out of 30 patients (23.33%), of which 4 (57.14%) occurred in the supraspinatus tendon, consistent with the available literature⁸⁵. Of these 7 tears 4 (57.14%) showed retraction as a consistent finding which can be correlated with the study by Farley *et al* in which 31 patients had full thickness tear which was proven on open surgery/arthroscopy out of which 18(58.06%) showed retraction.²⁰ In a study conducted on 2,436 shoulder, MRI examinations were done over a period of 67-months from September 1996 to April 2002. MRI findings of teres minor abnormality was seen in 0.8% only among the study population⁹⁹. None of the Teres minor in our study showed any abnormality.

Comparison of Final Diagnosis with MRI, USG and Clinical diagnosis: Final diagnosis was made by arthroscopy/surgery keeping them as gold standard. In our study clinical diagnosis had sensitivity of 100%, specificity of 0%, PPV of 83.33%, NPV of 0%, diagnostic accuracy of 83.33% with kappa degree of agreement 0. This is consistent with a meta-analysis (2012)²¹ which suggests that the diagnostic accuracy of orthopedic shoulder exams is overestimated, and that these exams are only rarely useful to differentiate RC tears. While some shoulder examination tests had high sensitivities and others had high specificities, no single test had both a high specificity and a high sensitivity. Further, the lack of precise techniques and subjective interpretation of these exams leads to substantial interobserver variability. In our study USG had a sensitivity of 64%, specificity of 100%, PPV of 100%, NPV OF 35.71%, diagnostic accuracy of 70% and kappa degree of agreement of 0.37. This is consistent with study done by Cynthia L. Miller *et al* in which bilateral rotator cuff sonography was performed on 56 patients referred for shoulder arthrography to detect rotator cuff tears and showed that USG had a sensitivity of 58%, specificity of

93% and overall predictive value of 72%. These results suggest that a positive sonographic reading is more reliable than a negative one.¹² In our study MRI had a sensitivity of 92%, specificity of 80%, PPV of 95.83%, NPV of 66.67%, diagnostic accuracy of 90% and kappa degree of agreement of 0.66. This is consistent with study done by Zlatkin MB *et al* who studied diagnostic performance of MRI in rotator cuff tears and reported sensitivity, specificity and accuracy of 91%, 88% and 89% respectively for all rotator cuff tears.¹⁰

CONCLUSION

Peribicipital tendon fluid, joint effusion, bursal fluid and acromio-clavicular joint hypertrophy have significant association with rotator cuff tears. Pain is the most common presenting complaint with decreased range of motion a common manifestation of rotator cuff tears. Most commonly involved tendon is supraspinatus. Partial tears are more common than the full thickness tears. Among the partial tears most common are articular surface tears. No single clinical examination test has both a high specificity and a high sensitivity, therefore the diagnostic accuracy of shoulder examination is overestimated and these exams are only rarely useful to differentiate rotator cuff tears. USG is less reliable in detecting rotator cuff tears than previously reported and a positive sonographic reading is more reliable than a negative one. MRI is more sensitive and has highest diagnostic accuracy in detecting rotator cuff tears as compared to USG and clinical diagnosis.

REFERENCES

1. Stephen N. Wiener, William H. Seitz, Jr. Sonography of the shoulder in patients with tears of rotator cuff: Accuracy and value for selecting surgical options. *AJR*. Jan 1993; 160:103-107.
2. Roberts MC, Esterhai JC, Kressel HY, Spindler High resolution surface coil MRI of the joints. *Radiographics* 1983; 176:37-38.
3. Utthoff.H.,Sano,H.Pathology of failure of the rotator cuff tendons. *Orthop,Clin.North Am.*28 (1):31-41, 1997
4. Ozaki.J, Fullmoto.S, Nagkagawars.Y, Mambara.K, Tamai.S. Tears of the rotator cuff of the shoulder associated with pathological changes in the acromion.A study in cadaver. *J. Bone Joint Surg.*70-A: 1224-1230, 1988.
5. McConville.O.R, Iannoni.J.P. Partial thickness tears of the rotator cuff: evaluation and management. *J.Am.Acad.Orthop.Surgeons* 7:32-43, 1999.
6. Steven DN, Michael BZ, Jerry S, Brain J,John W. Imaging of the rotator cuff: Peritendinous and Bone Abnormalities in Asymptomatic Population. *AJR* 1996;166:867-869.

7. David W.S, Phillip F.J, Miriam AB. *Diagnostic Imaging: orhtropedics*,1st ed.Canada:Amirsys,2004.
8. Yamamoto A, Takagishi K, Osawa T, et al. Prevalence and risk factors of a rotator cuff tear in the general population. *J Shoulder Elbow Surg.*2010;19:116-120
9. Urwin M, Symmons D, Allison T, Brammah T, Busby H, Roxby M, et al. Estimating the burden of musculoskeletal disorders in the community: the comparative prevalence of symptoms at different anatomical sites and the relation to social deprivation. *Ann Rheum Dis* 1998; 57:649-655.
10. Zlatkin, Michael B. *MRI of the Shoulder*, 2nd ed, Philadelphia:Lippincott Williams and Wilkins, 2003.pg 50.
11. Depalma A.FJ. *Surgery of the shoulder*.Philadelphia,B.Lippincott 1983:211- 231.
12. Martin-Hervas C, Romero J, Navas-Acien A, Reboiras JJ, Munuera L. Ultrasonographic and MR Imaging of rotator cuff lesions compared with arthroscopy or open surgery findings. *J Shoulder Elbow Surg.*2001; 10(5): 410- 5.
13. Doughlas P, Eric E, Justin Q, Mark C, Robert L. Association of peribicipital tendon fluid with rotator cuff abnormalities: Degree of correlation with tears of the anterior and superior portions of the rotator cuff. *AJR* 2003; March; 180:633-639.
14. Hollister MS, Mack LA, Patten RM, et al: Association of sonographically detected subacromial/subdeltoid bursal effusion and intraarticular fluid with rotator cuff tear. *AJR Am J Roentgenol* 1995 Sep; 165(3): 605-608.
15. John W Read, Mark Perko. Diagnostic accuracy for impingement syndrome, rotator cuff tear and biceps tendon pathology. *J. Shoulder Elbow Surg* 1998; 7:264-271.
16. Bigliani LU, Ticker JB, Flatow EL, Soslowsky LJ, Mow VC. The relationship of acromial architecture to rotator cuff disease. *Clin Sports Med.* 1991; 10(4):823-38.
17. Ellman H, Hanker G, Bayer M. Repair of the rotator cuff and study of factors affecting reconstruction. *J.Bone Joint Surg.* 70A:124: 1998.
18. Glenn A, Dirk E, Andrew G, Jeffrey M. High field and low field MR imaging of superior glenoid labral tears and associated tendon injuries: *AJR* April 2000; 174:1107-114.
19. Huang LF, Rubin DA, Britton CA. Greater tuberosity changes as revealed by radiography: lack of clinical usefulness in patients with rotator cuff disease. *AJR* 1999; 172:1381-1388.
20. Farley TE, Christian NH, Lynn S et al. Full Thickness Tears of the Rotator Cuff of the Shoulder: Diagnosis with MRI. *AJR* 1992; 158:347-351.
21. Giles W, Aziz B, Salvatore C, Andrew H.N, Robinson. The 'drooping' and 'hornblower's' sign in evaluation of rotator cuff tears: *The Journal of Bone and Joint Surgery* 1998; 80-B(4):624-628.
22. Cynthia L. Miller, David Karasick, Alfred B. Kurtz, John M. Fenlin Jr. : Limited sensitivity of USG for detection of rotation cuff tears. *J Skeletal Radiology*; 18(3):179-183.1989.

Source of Support: None Declared
Conflict of Interest: None Declared